

EVALUATING THE ROLE OF PROTON MAGNETIC RESONANCE SPECTROSCOPY IN CHARACTERIZATION OF INTRACRANIAL LESIONS

**Mahmoud I. Aboelnor, Mohamed E. Elhawary,
Mohamed A.E. Mahmoud, Mohamed A.M. Saad**

*Department of Radiodiagnosis, Faculty of Medicine,
Fayoum University, EGYPT*

E-mails: Mahmod_ibrahim@yahoo.com,
melhawary@yahoo.com,
mohamedsalem_1997@hotmail.com,
saadams71@yahoo.com

ABSTRACT

The aim of this study is to evaluate the role of MR spectroscopy in characterization of intracranial lesions including differentiation of neoplastic from non-neoplastic lesions as well as grading of malignant lesions in clinical practice, based on clinician opinion, requesting MR spectroscopy evaluation, in whom the clinical situation could not have explained by the results of conventional imaging or their results were equivocal warranting further work up.

The spectroscopy technique was done utilizing short intermediate and short TE sequences over the lesion, the sensitivity, specificity, positive predictive value (PPV), negative predictive value (NPV) and accuracy of the results of MRI spectroscopy and separately for each of its parameters compared to the result.

Keywords: *Magnetic resonance imaging, Magnetic resonance spectroscopy, Brain tumors, Gliomas, Cerebral metastasis, Inflammatory brain diseases, Cerebrovascular stroke*

INTRODUCTION

Intracranial tumors are a significant health problem. The annual incidence of primary and secondary central nervous system neoplasms ranges from 10 to 17 per 100,000 persons. (1)

Inflammatory diseases of the central nervous system (CNS) are playing an important role in the clinical practice of neuroradiology: Infections of the CNS frequently involve immunocompromised patients and are being accompanied increasingly more with the employment of innovative and aggressive immunosuppressive and immunomodulatory therapies. Noninfectious inflammation, such as multiple sclerosis, accounts for about 10% of all neurological disease. (2)

Brain abscesses and brain tumors may have similar clinical presentations. For example, only 50% brain abscess patients have fever, which could be masked by corticosteroid therapy.

The differential diagnosis of brain abscesses versus cystic or necrotic tumors may be difficult based on computed tomography (CT) or magnetic resonance (MR) imaging findings. However, the strategies of management for abscess and neoplasm are very different, and it is especially imperative to have a correct diagnosis before any surgical intervention. (3)

MRS can be used to quantify various metabolites within a sample of tumor tissue. These metabolites include the neuronal marker N-acetyl aspartate (NAA); choline, a cell membrane component; lactate, for glycolysis and necrosis; and Creatine, a marker for energy metabolism. (4)

In general, primary brain tumors demonstrate reduced levels of NAA and increased levels of choline relative to normal brain tissue. Elevated choline levels are thought to represent areas of increased tumor cellularity and proliferative activity where is decreased NAA is thought to represent decreased neuronal density and viability found in gliomas. (5)

MR spectroscopy shows characteristic metabolites in pyogenic abscesses, distinct from those in cystic or necrotic tumors. (4)

PATIENTS AND METHODS

The study was conducted over 4 years including about 90 patients (2012 to 2015) 35 of them were excluded from the study because of lack of confirming objective methods which in this study were histopathology, and follow up in cases not candidate for surgical intervention.

55 patients were included in this study matching objective criteria in confirming the diagnosis.

All patient had preliminary full MRI examination in the form of axial T1, T2, FLAIR and Diffusion weighted images as well as sagittal t1 weighted images in addition to post contrast coronal axial and sagittal T1 post contrast.

The spectroscopy technique was done utilizing long intermediate and short TE sequences over the lesion, trying as much to avoid necrotic portions and contamination by surrounding tissue (as much as possible)

The sensitivity, specificity, positive predictive value (PPV), negative predictive value (NPV) and accuracy of the results of MRI spectroscopy and separately for each of its parameters compared to the final result,

Ethical issues

No personal data were disclosed

All images included in the study were anonymous.

We used methods of confirmation

Operative findings and histopathology.

Follow up and definite improvement or cure

MR Technique

Magnetic resonance imaging was performed on a 1.5 T MRI system (Integra; Philips Medical Systems, Netherlands) or 1.5 T MRI system (Panorama; Siemens Medical Systems, Germany) using a head coil.

Total study time ranged from 40 to 60 minutes.

MR spectroscopy

T1- and T2- weighted imaging were used for voxel localization. The selection of voxel position in the estimated center of the lesion was determined visually by examining the MR images in three orthogonal planes (sagittal, coronal, and axial) to define the volume of interest. A voxel of 1.5x1.5x1.5 cm to 2x2x2 cm was used, depending on the size of lesion, was placed within the edge of the lesion whenever possible to assess brain parenchyma and not areas of necrosis

The presence or absence of resonance peaks for choline, creatine, NAA, lipid, lactate, were recorded for each patient. In addition, the Cho/Cr, Cho/NAA and NAA/Cr ratios were calculated.

The peak areas of NAA, choline, and creatine were also measured in the corresponding contralateral normal-appearing brain tissue. Thus, each patient served as his or her own control.

Diagnostic Criteria

1- Final diagnosis:

We divided the disease status into either neoplastic and non-neoplastic group according to the pathological, surgical and clinical data.

Abscess: - The diagnosis of brain abscess was made by pathology or stereotactic aspiration biopsy or on basis of clinical symptoms, laboratory data, and improvement in the follow-up imaging after antibiotic therapy.

Neoplastic lesions: - All primary neoplasms were confirmed by surgery. The patient with metastatic tumor was diagnosed on the basis of clinical and radiological findings and had pathologically proven primary cancer

The patient with recurrence most of cases diagnosis made based upon conventional MRI and MRI spectroscopy

Brain vascular insult: - The diagnosis was based upon:

Evident clinical improvement.

Follow up MRI.

Follow up MR spectroscopy.

2- MR Spectroscopy:

The diagnosis was based upon: -

Levels of brain metabolites compared to the other side.

Ratios of different metabolites compared to the other sites.

On the basis of these criteria, the patients were categorized into one of two groups, neoplastic group and non-Neoplastic group.

The neoplastic group was divided into high, grade, low grade and intermediate grade.

Lymphoma metastasis and meningioma have special patterns

Statistical Analysis:

Data were encoded and entered on an IBM compatible computer using computer programs Microsoft Excel 2010 (Microsoft Corporation, USA) and SPSS version 18 (Statistical Package for the Social Science; IBM Corporation, USA). Data were statistically described in terms of range, mean, standard deviation (* SD), frequencies (number of cases) and relative frequencies (percentages) when appropriate. Sensitivity, specificity, positive predictive value (PPV), and negative predictive value (NPV) of MRS with respect to final diagnosis for differentiation of neoplastic from non-neoplastic lesions were calculated to assess the efficacy of these modalities. They were calculated using a 2 x 2 contingency table displayed in Table (1).

Table 1. The 2 x 2 contingency table between the case number of the final diagnosis and the result according to the imaging modalities

MRS	Final diagnosis +ve -ve		Total
	+ve	a (True Positive)	b (False Positive)
-ve	c (False Negative)	d (True Negative)	c+d (All test negative)
Total	a+c (All diseased)	b+d (All disease free)	a+b+c+d (Grand total)

Sensitivity = $a / (a + c)$ - Specificity = $d / (b + d)$ - PPV = $a / (a + b)$ - NPV = $d / (c + d)$
Total accuracy = $a + d / (a + b + c + d)$

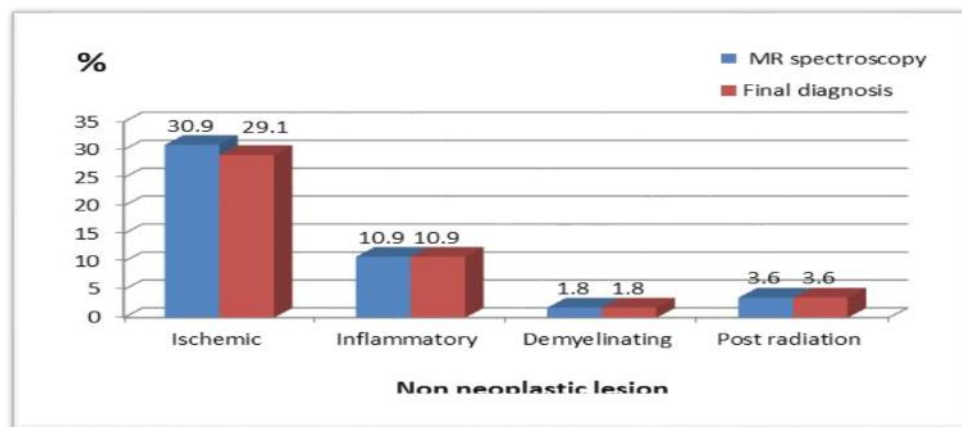
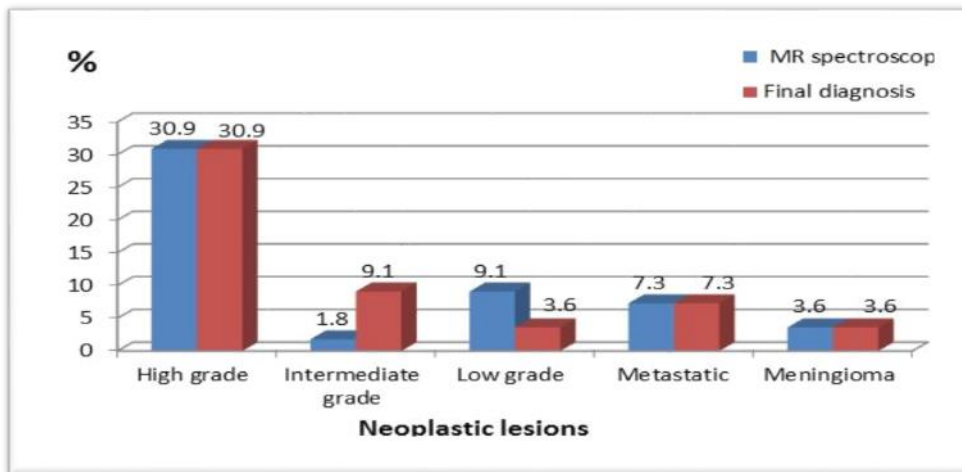
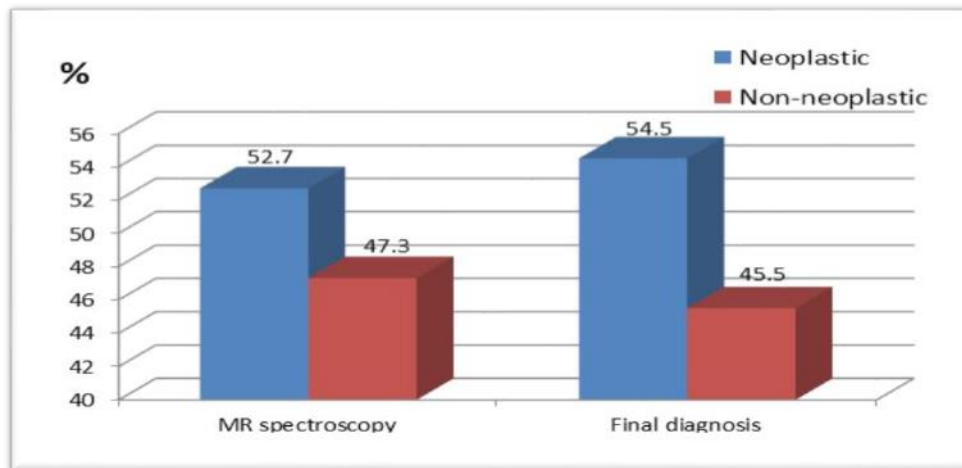
RESULTS

1- Demographic data

This study included 55 patients. Their ages ranged from 15 - 70 years with a mean of 47.55 ± 13.05 (mean \pm SD). Patients were distributed upon two groups namely the neoplastic group and the non-neoplastic group according to the final diagnosis. The neoplastic group included 29 patients while the non-neoplastic group included 26 patients.

Table 2. Distribution of patients according to their demographic characteristics

	All patients	Neoplastic	Non-neoplastic
Age	Mean \pm SD (range)		
	47.55 ± 13.05 (15-70)	48.03 ± 13.67 (15-70)	46.27 ± 11.56 (25-63)
Sex	N (%)		
Male	40 (72.7%)	17 (58.6%)	23 (88.5%)
Female	15 (27.3%)	12 (41.4%)	3 (11.5%)



Figures 1,2 &3. Charts comparing results of final diagnosis and spectroscopy diagnosis

Table 6. State of concordance between MR spectroscopy and final diagnoses in the studied sample

Diagnoses (by MR spectroscopy)	Concordance N (%)	Discordance N (%)
Neoplastic:	25 (86.2)	4 (13.8)
high grade	16 (94.1)	1 (5.9)
Intermediate grade	1 (100.0)	0 (0.0)
Low grade	2 (40.0)	3 (60.0)
Metastatic	4 (100.0)	0 (0.0)
Meningioma	2 (100.0)	0 (0.0)
Non-neoplastic:	25 (96.2)	1 (3.8)
Ischemic	16 (94.1)	1 (5.9)
Inflammatory	6 (100.0)	0 (0.0)
Demyelinating	1 (100.0)	0 (0.0)
Post radiation	2 (100.0)	0 (0.0)
Total	50 (90.9)	5 (9.1)

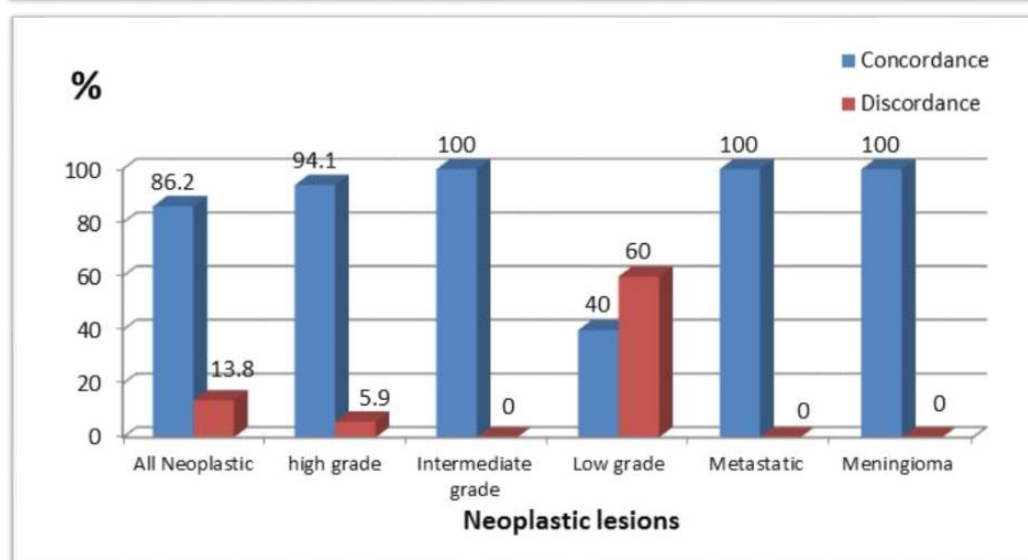
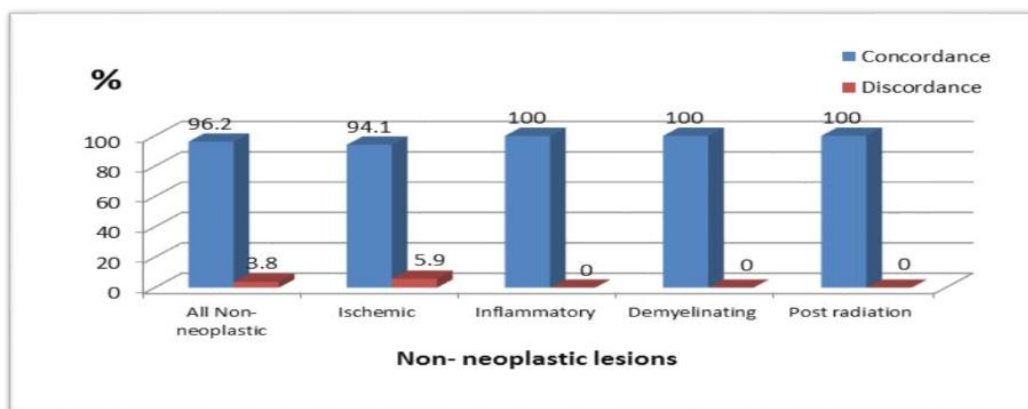
**Figures 4&5.** Charts Demonstrating State of concordance between MR spectroscopy and final diagnoses in the studied sample

Table 7. Diagnostic accuracy of MR spectroscopy parameters compared to final diagnosis in differentiating neoplastic from non-neoplastic

Parameter	Sensitivity	Specificity	+ve PV	-ve PV	Total accuracy
Choline	76.7	100.0	100.0	78.1	87.3
Lipid	53.3	48.0	55.2	46.2	50.9
Lactate	76.7	52.0	65.7	65.0	65.5
Choline/creatine ratio	76.7	96.0	95.8	77.4	85.5
Choline/N-acetyl aspartate ratio	76.7	96.0	95.8	77.4	85.5
Collective MR spectroscopy	96.7	100.0	100.0	96.2	98.2

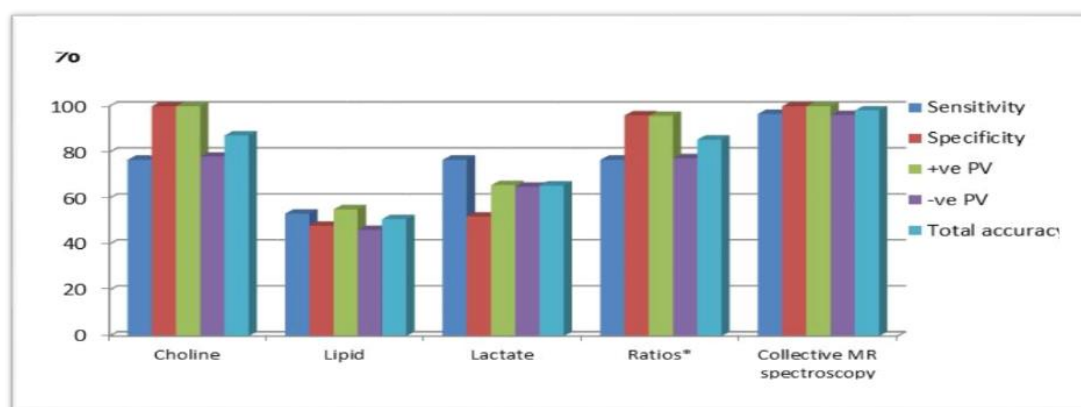
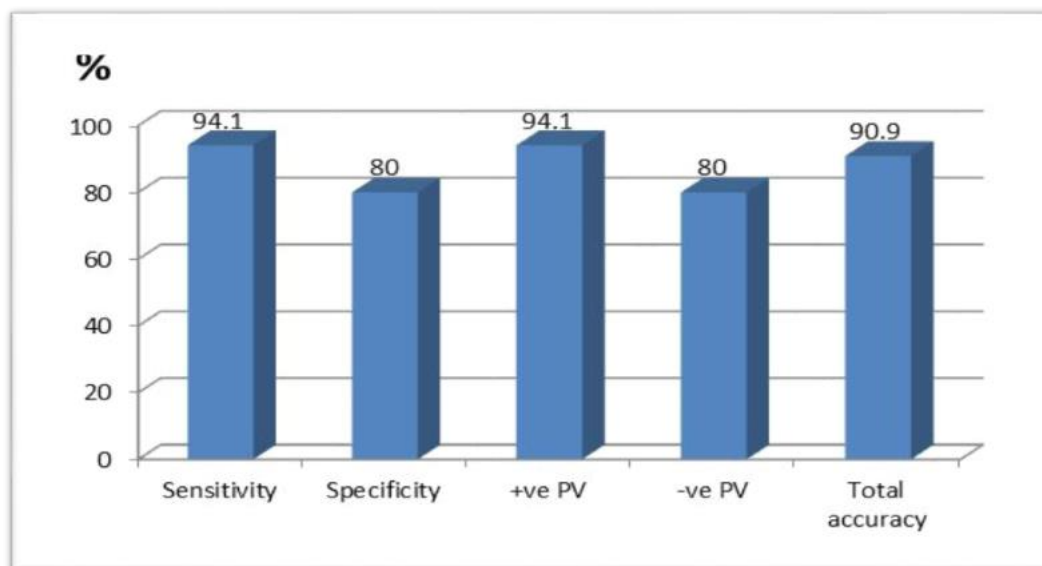
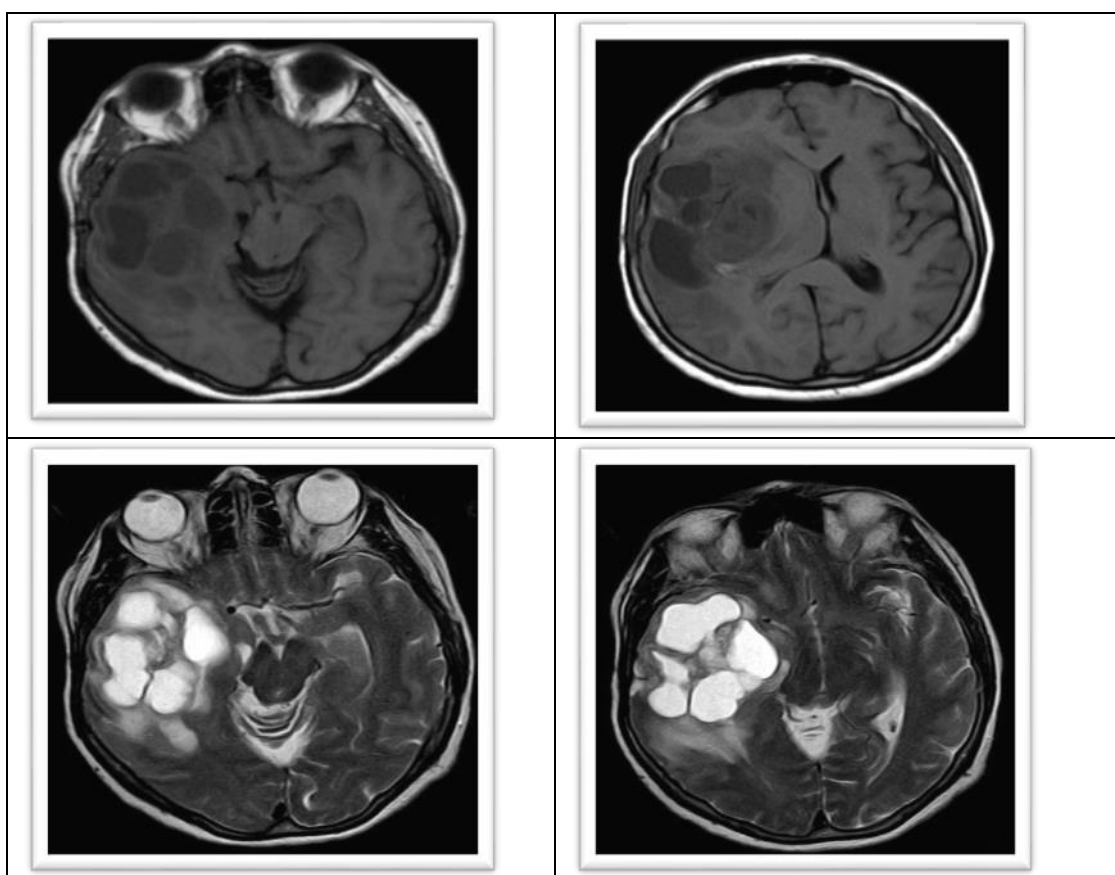
**Figure 6.** Chart demonstrating diagnostic accuracy of MR spectroscopy parameters compared to final diagnosis in differentiating neoplastic from non-neoplastic**Figure 7.** Chart of Diagnostic accuracy of MR spectroscopy compared to final diagnosis in differentiating high grade neoplasm from other grade (intermediate & low) neoplasm from other grade (intermediate & low)

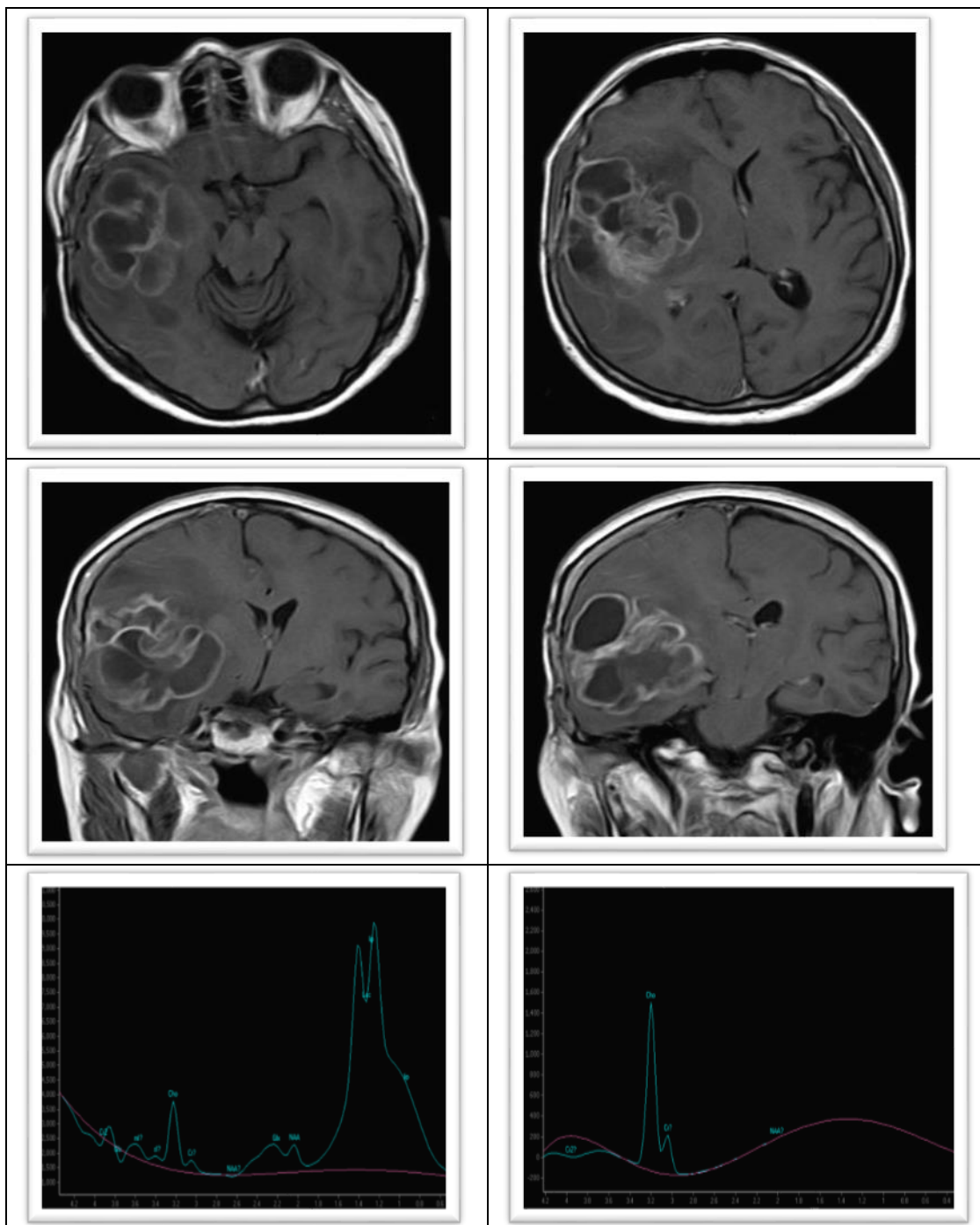
Table 8. Diagnostic accuracy of MR spectroscopy compared to final diagnosis in differentiating high grade

Parameter	Sensitivity	Specificity	+ve PV	-ve PV	Total accuracy
Collective MR spectroscopy	94.1	80.0	94.1	80.0	90.9

Demonstration cases

Case (1) Female patient age 63 years complaining of convulsions and left side hemiparesis for 3 months.



**Technique**

Axial T1, T2.

Post contrast axial and coronal T1.

Long and short TE spectroscopy.

Findings

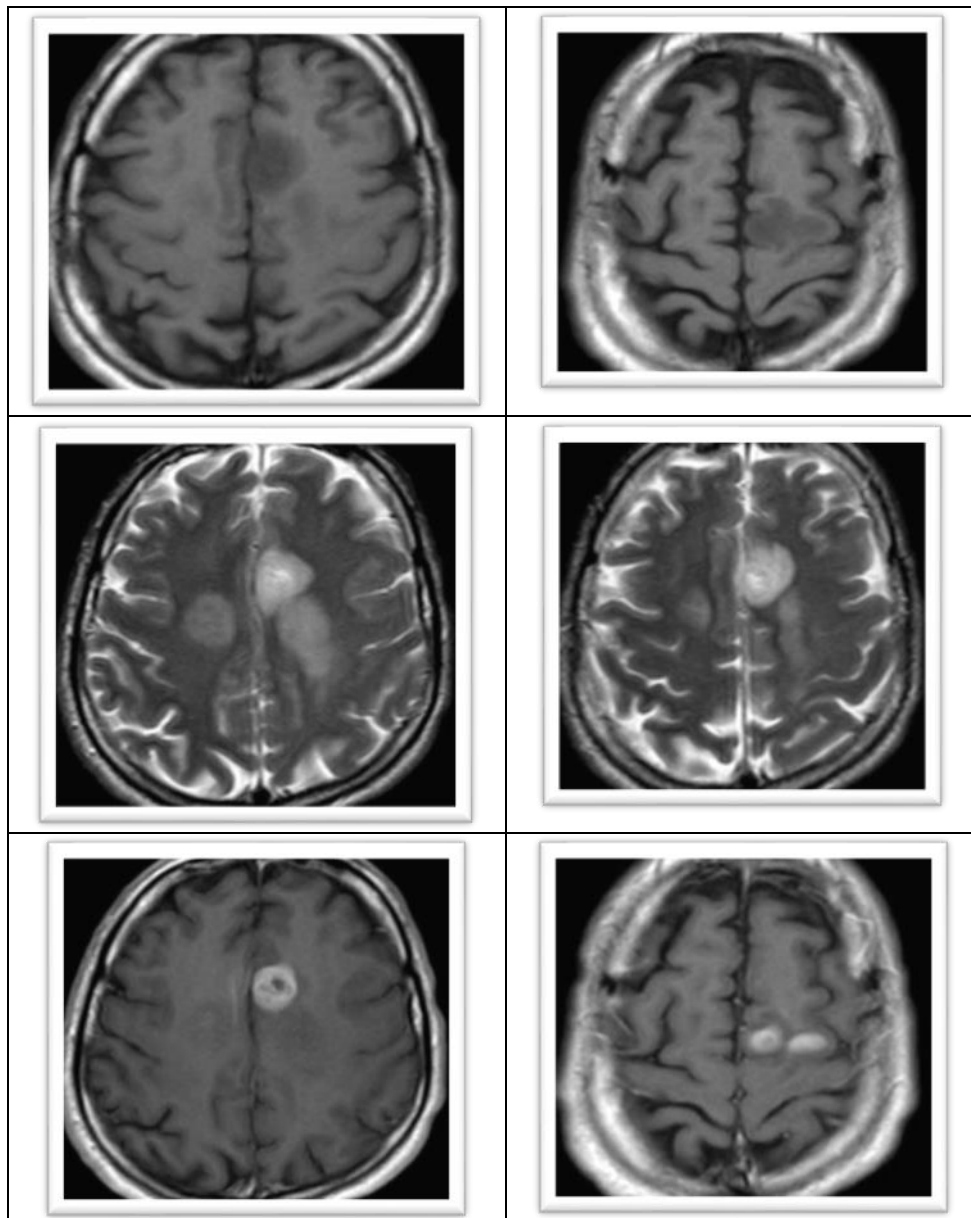
Her contrast enhanced MRI shows a multiloculated cystic marginally enhancing lesion at the right temporoparietal region.

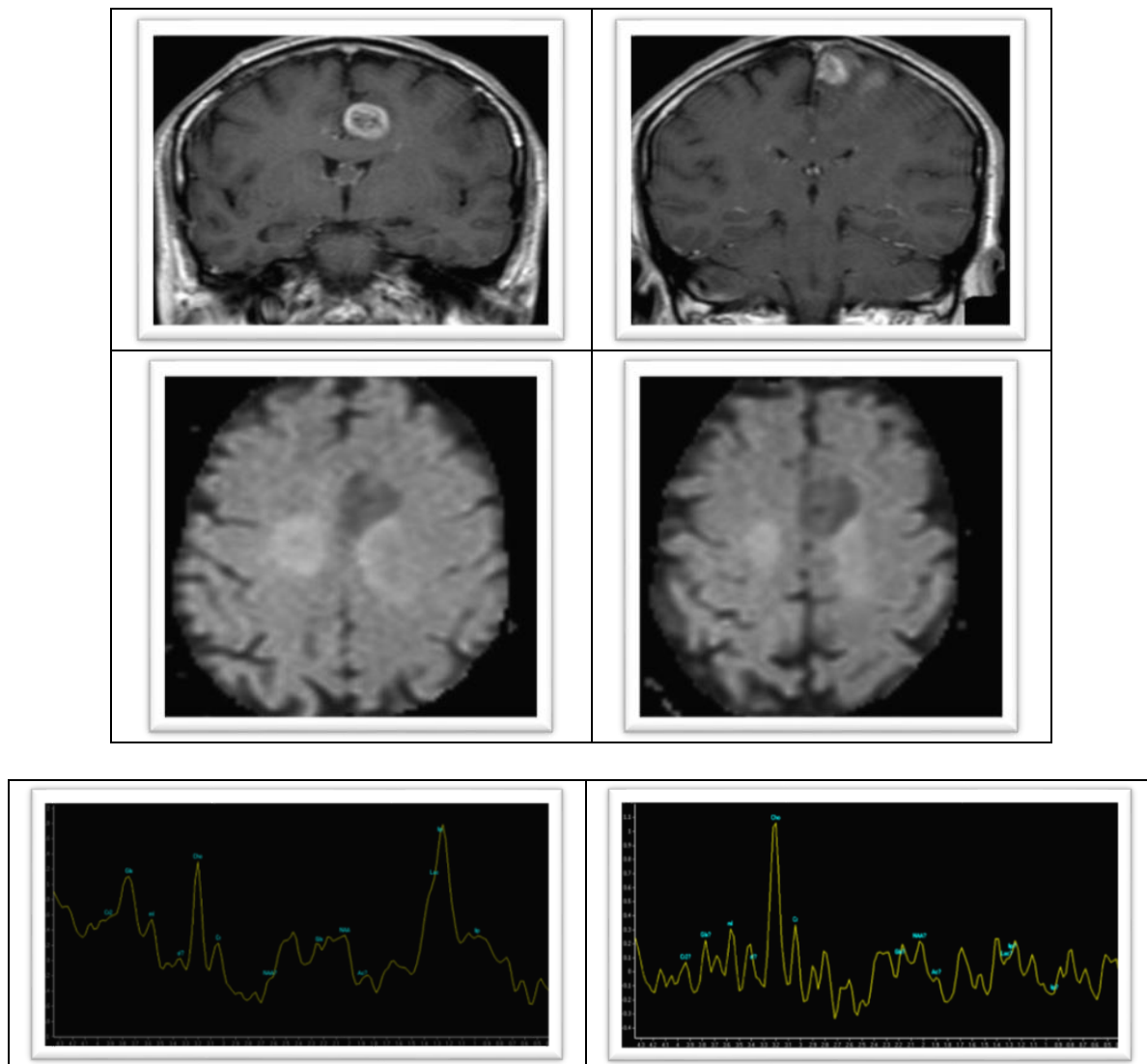
Her MRS shows choline peak and elevated lipids. Note that the lipid appears in the short TE and not in the long TE confirming that it is lipid and not lactate. Absence of NAA and markedly reduced creatine was also noted. Cho/Cr ratio is 4.7.

Diagnosis

The patient was operated upon and diagnosed as anaplastic astrocytoma.

Case (2) Male patient age 50 years known to have bronchogenic carcinoma. He complains of headache and MRI brain was requested.





Technique

Axial T1, and T2.

Post contrast coronal T1.

Axial diffusion weighted images.

Long and short TE spectroscopy.

Findings

His contrast enhanced MRI shows multiple marginally enhancing lesions at the both parietal regions.

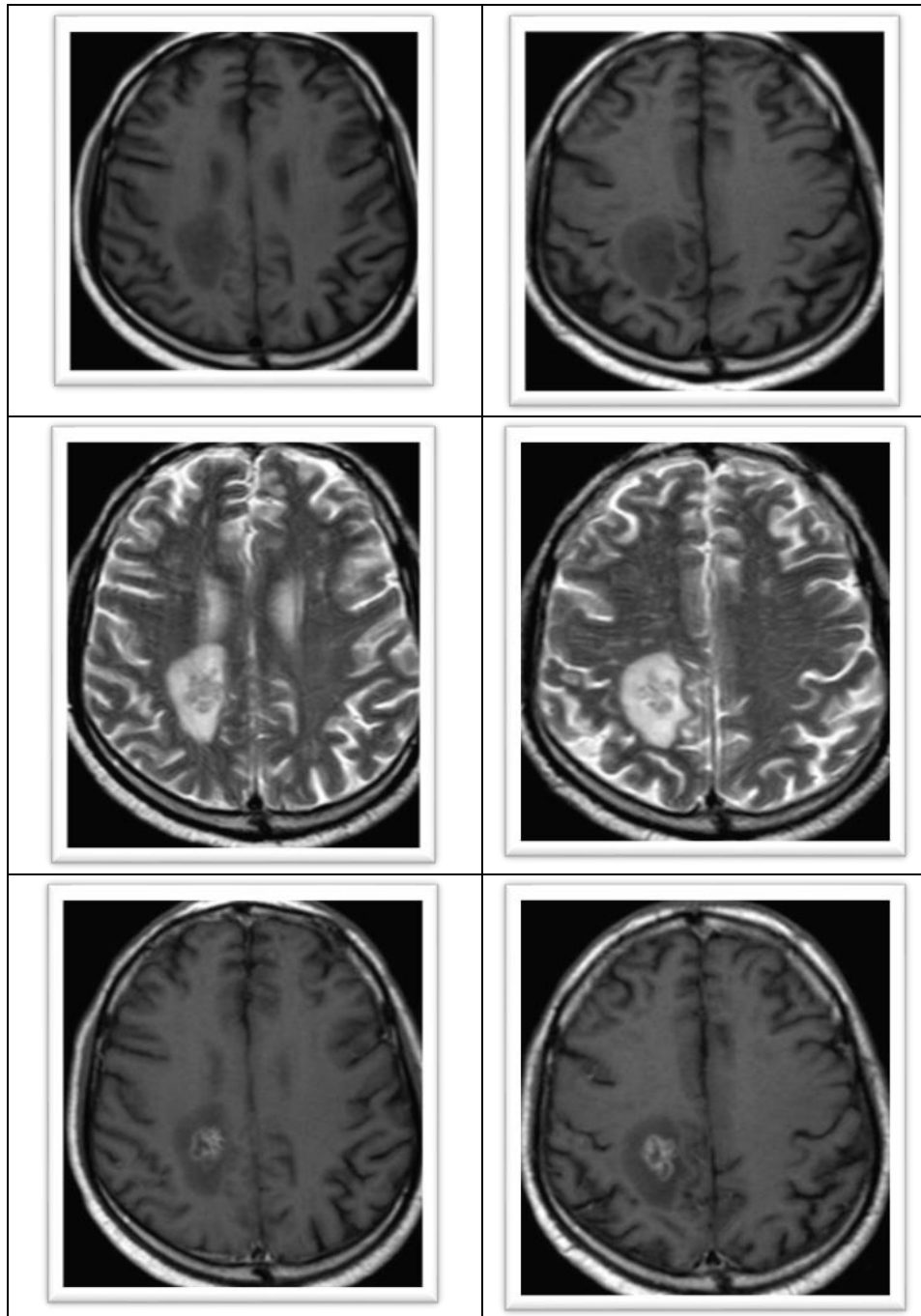
DWI show facilitated diffusion at the left parietal parafalcine lesion.

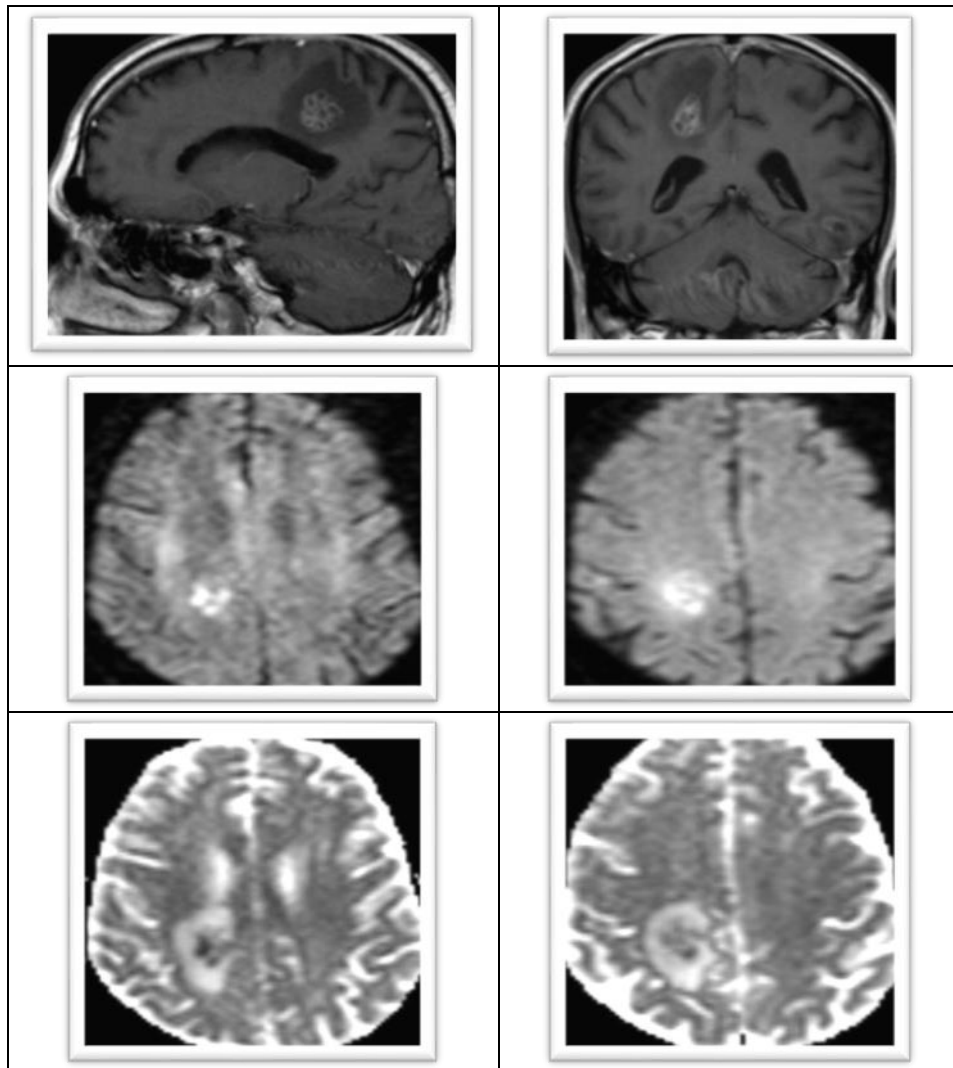
MRS was obtained from the largest lesion located at the left parietal parafalcine region. It shows choline peak and elevated lipids that was again confirmed by absent peak at long TE. Other normal brain metabolites as NAA and creatine are moderately reduced. Cho/Cr ratio is 3.1, Cho/NAA ratio is 3.3 and NAA/Cr ratio is 0.9.

Diagnosis

Based on clinical data and MRI findings the patient was diagnosed as having brain secondaries.

Case 3 Male patient age 53 years known immunocompromised due to immunosuppressive drugs received after renal transplantation. He is complaining of fever, headache and leukocytosis.



**Technique**

- Axial T1 and T2.
- Post contrast axial sagittal and coronal T1.
- Axial diffusion and ADC.
- Long and short TE spectroscopy

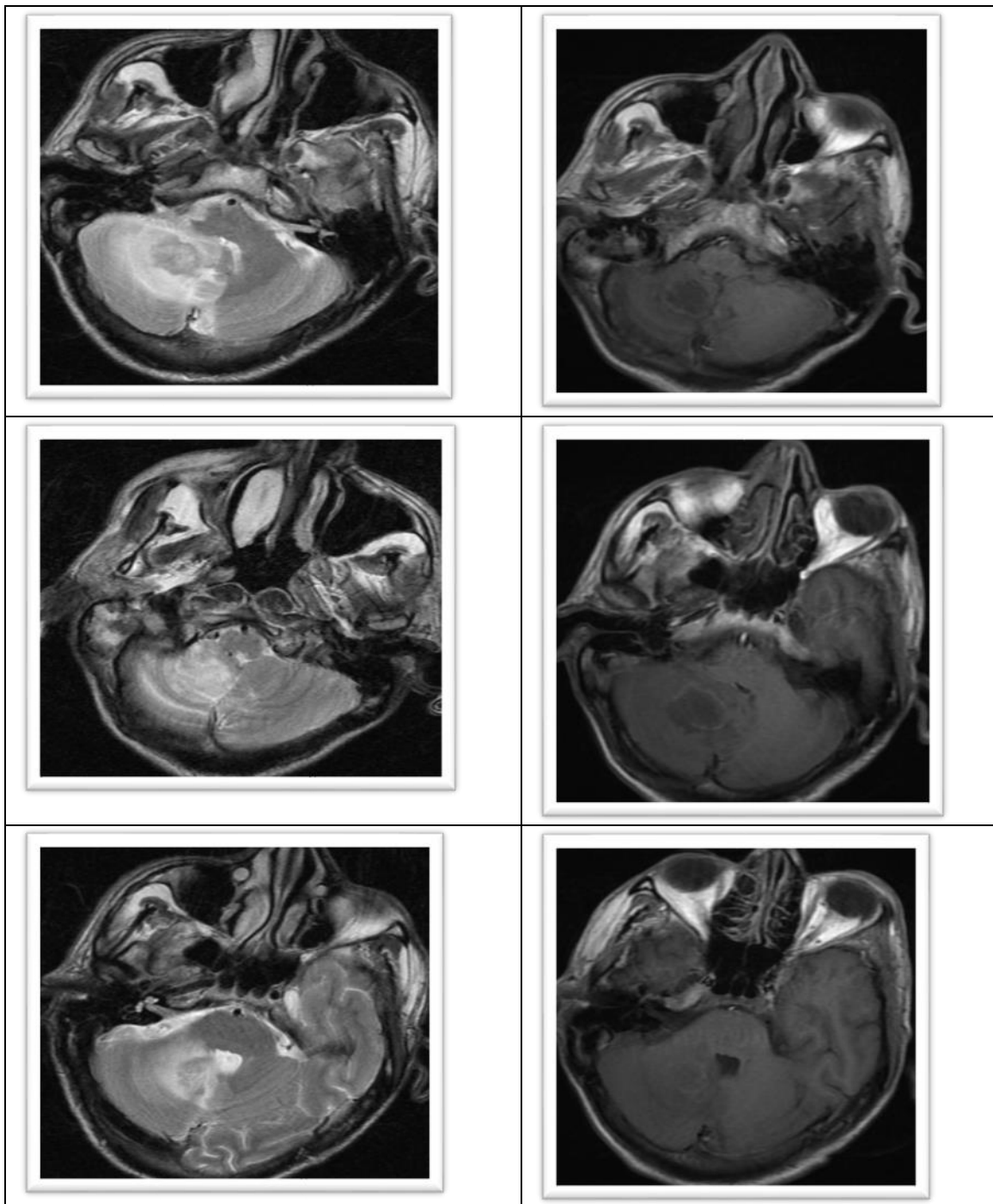
Findings

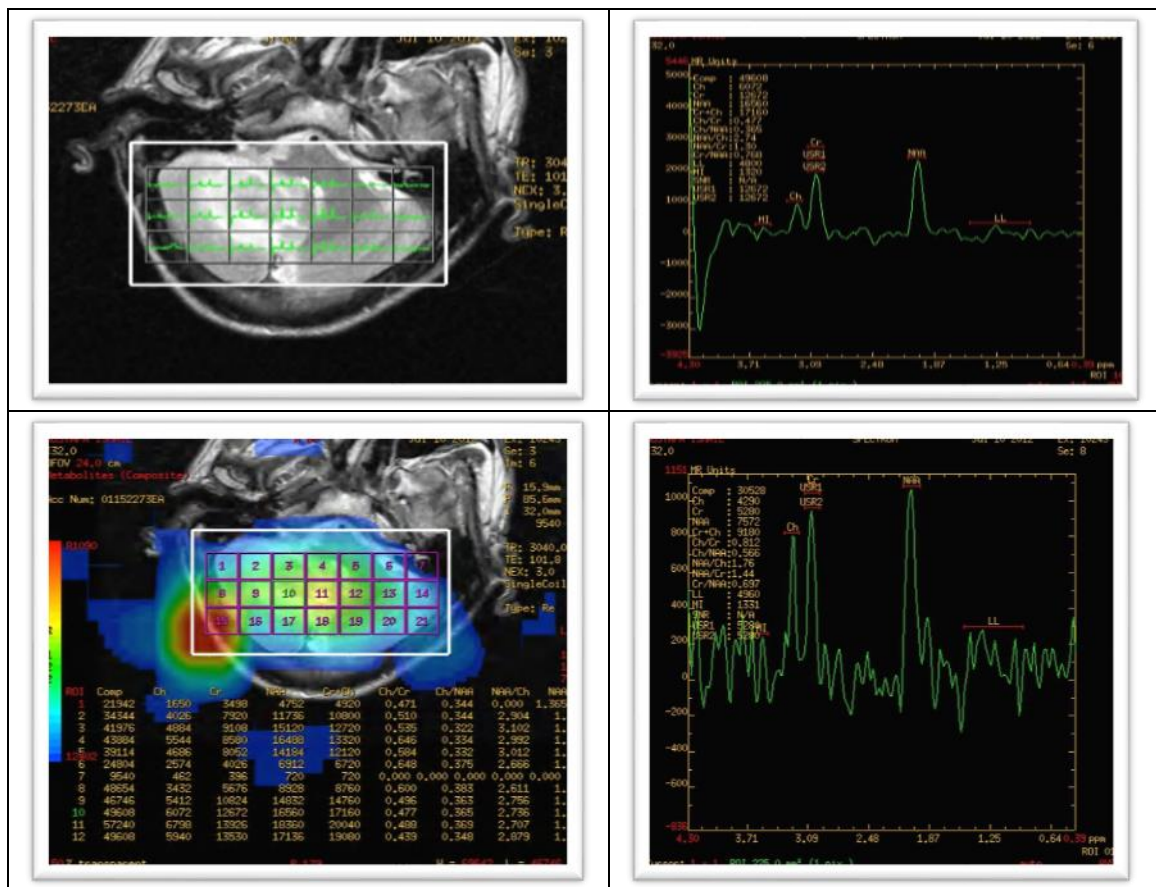
- His contrast enhanced MRI shows right posterior parietal ring enhancing cystic space occupying lesion.
- MRS shows amino acid, acetate and lactate peaks. Choline was not detected in this patient. NAA was reduced however creatine was detected.

Diagnosis

- He was diagnosed as brain abscess and showed improvement upon antibiotic and medical treatment.

Case (4) 51 years' male patient with recent of liver transplantation presented with fever convulsions and disturbed conscious level





Technique:

- Multivoxel images was done at the cerebellar hemispheres with comparison between two sides

Findings:

- Choline which is the neural marker for cellular growth and turn over shows slight increase compared to the normal side.
- N. acetyl aspartate shows mild decrease compared to the normal side.
- Also creatine which is the most stable neural marker also shows mild decrease compared to the other side.
- These is no lipid lactate lactase peak.
- The is diffusion restriction noted over the edge of the lesion.

Opinion:

- MRI spectroscopy findings in adding to the clinical history of liver transplantation and possible immunosuppression are in favor of an inflammatory lesion? Abscess.

Confirmed diagnosis

- The patient underwent surgical draining and proven to fungal abscess due to immunocompromised state

DISCUSSION

The most common metabolites within normal brain tissue that have been assigned to resonance lines in human proton MR spectroscopic studies are; N-acetyl aspartate (NAA), Choline (Cho), Creatine (Cr), glutamate – glutamine (GLx), and myo-inositol (MIns), finally Lactate (Lac) and lipids (Lip) which are usually abnormal brain metabolites.

Therefore, frequently asked questions: -

Is it a tumor?

This is one of the most frequently asked questions (FAQ) to radiologists. Spectroscopy is valuable in cases when conventional MR imaging and the clinical history are ambiguous. When the differential diagnosis includes stroke, focal cortical dysplasia or herpes encephalitis and neoplasm, the finding of an elevated Cho peak makes the diagnosis of tumor more likely.

There are caveats as well, and the radiologist must be well aware that some non-neoplastic focal lesions may show elevated Cho. For example, an acute giant demyelinating plaque could mimic an HGG on both MRI and 1H-MRS. Acute demyelinating lesions may show elevated Cho and decreased NAA signal. (6)

Is it a GBM, metastasis, or an abscess?

The second FAQ is the differential diagnosis of a ring enhancing mass. The best strategy is to use a multivoxel PRESS sequence with intermediate TE to look for elevation of Cho in the enhancing rim and in the perilesional T2 hyper intensity. If Cho is elevated in both areas, a likely diagnosis of GBM may be suggested. (7)

Elevation of Cho in the enhancing rim but not in the surrounding tissue would suggest the diagnosis of metastasis. In spectra derived from the necrotic/cystic core of the mass, accumulation of lipids or lactate without elevated Cho is not a specific finding; thus, the acquisition of an additional single voxel spectrum with short TE would be helpful to detect the presence of other minor peaks beyond lactate: succinate (2.42 ppm), acetate (1.9 ppm), or amino acids such as leucine (3.6 ppm), alanine (1.5 ppm), and valine (0.9 ppm)

The detection of few or all of these peptides and amino acids to confirms the diagnosis of a pyogenic abscess. (8)

What's the grade of this glioma?

Whether 1H-MRSI is useful for grading of gliomas or not remains a controversial issue. There is a body of evidence in the literature that both Cho/NAA and Cho/Cr increase with cellular density and mitotic index. However, in the individual cases it may be difficult to assign a grade to a mass on the basis of 1H-MRS alone. It is therefore useful to review changes in metabolic profile occurring during the malignant transformation from diffuse to anaplastic astrocytoma: the NAA signal falls to the baseline while the Cho signal increases with higher cell density and proliferation. The Cho/NAA ratio is likely the most sensitive index for tumor cell density and proliferation. This ratio can be used as a

marker of tumor infiltration. Cho/NAA reaches the highest values in anaplastic astrocytomas and GBM.

Elevated Cho/NAA values can be found in the solid components of the mass when the tissue is still well perfused and oxygenated. Once components of the mass become hypoxic or their apoptotic index increases, a significant drop of the Cho signal occurs in those areas, sometime associated with accumulation of lipids. The Cr signal also changes during this malignant transformation. Cr signal is usually normal or slightly elevated in differentiated and oxygenated astrocytomas. Elevation of Cr is more commonly seen in astrocytoma infiltrating the cortex compared to those growing in the white matter. In astrocytomas infiltrating the gray matter in the cortex or in the basal ganglia and thalami, both Cho and Cr may be elevated with the Cho/Cr approaching unity or even slightly below. Then Cr may drop significantly when new clones with greater proliferation and less differentiating capacities will arise and prevail. Despite several ¹H-MRSI studies which have reported high diagnostic accuracy in glioma grading, (9) (10) (11) (12)

In this study 55 cases were included 30 of them were neoplastic including 17 high grade gliomas (including glioblastoma), 5 intermediate grade, 2 low grade 4 metastatic cases 2 meningioma cases in addition to 25 cases non neoplastic including 16 cases ischemic insult, 6 cases inflammatory, 1 case demyelination and 2 cases post irradiation (based on final diagnosis)

This study was done on broad spectrum sample based on clinical point of view, (as in practice the routine imaging way of work is that the clinician asks for the examination based on his need to for decision to precede in treatment of cases).

We must say that for us as radiologists some of cases in this study could diagnosed upon conventional imaging yet they meet the inclusion criteria that we put in study respecting the clinical suspicion and clinical point of view.

In this study we utilized not only the spectroscopy ratio but also their absolute ratios compared to similar normal areas on the contralateral side.

In this study we tried so much to put the boxes of voxel measurements upon the edge lesions to involve active viable non necrotic tissue.

In this study we excluded more than 20 cases of patient because they have blind end with no methods of confirmation for diagnosis

Also in some cases we accepted evident clinical improvement in addition to follow up images especially in cases of ischemic insult as it is not rational to do surgery in such cases.

Conventional imaging and diffusion weighted images acted as additional spot light and way to guide spectroscopy imaging.

In this study we found.

Significant increase in choline is found in all high grade neoplasm, we mean by significant increase (marked increase) is two folds' increase.

Yet mild increase less than two folds is present is low grade, intermediate grade, neoplasms and and many of conditions of associated with gliosis as the edges of abscess, healing of infarction and otherwise, and so we calculated the sensitivity upon two folds' increase.

N acetyl aspartate is neural marker reduced in all cases of insult and so in most of cases of brain insult apart from one case of mild ischemic brain insult.

Creatine is the most stable brain metabolite it is reduced at most of cases ranging between major reduction is cases of high grade neoplasms and mild reduction in mild insults.

So choline/creatine and choline/ N-acetyl aspartate are predictors of malignancy if ratios more are more than 2

We found lipid peak in 27 cases including all cases of high grade tumors, yet it's also presence in some cases of inflammatory lesions of the brain.

Also lactate peak is present in 35 cases including and inflammatory lesions some ischemic lesions and well as many of the neoplastic lesions leaning to lower grade neoplasms choline alone has Sensitivity of 76.7 % Specificity of 100.0 % +ve PV of % 100.0 -ve PV of 78.1% and total accuracy of 87.3 %.

Lipid alone has Sensitivity of 53.3 % Specificity of 48.0 % +ve PV of 55.2% -ve PV of 46.2% and total accuracy of 50.9 %.

Lactate alone has Sensitivity of 76.7 % Specificity of 52.0 % 65.7+ve PV of 65.7 % -ve PV of 65 % and total accuracy of 65.5 %.

Choline/creatine ratio alone has Sensitivity of 76.7 % Specificity of 96.0% +ve PV of 95.8 % -ve PV of 77.4 % and total accuracy of 85.5 %.

Choline/N-acetyl aspartate ratio alone has Sensitivity of 76.7 % Specificity of 96.0 % +ve PV of 95.8 % -ve PV of 77.4% and total accuracy of 85.5%.

Collectively MR spectroscopy as whole has 96.7 Sensitivity of 100.0 % Specificity of 100.0 % +ve PV of 96.2 % -ve PV of 96.2% and total accuracy of 98.2 %.

It is suggested that the high accuracy of spectroscopy diagnosis is aided by: High grade tumors namely glioblastoma multiform, high grade glioma and anaplastic astrocytoma are most common and taking large section of neoplastic brain lesions and their spectroscopy findings are very clear differentiating it from other lesions that have similar appearance in conventional MRI as they have different conventional findings.

The ischemic areas and vascular insults (infarction and encephalomalacia) have spectroscopy finding and short term follow up of conventional imaging is very helpful.

Intermediate grade and low grade tumor in our study are 6 cases while metastatic cases are only 4 cases this low number significantly reduced our ability to discuss the value of spectroscopy in their assessment.

Advanced MR imaging techniques are usually of little value in making the diagnosis in patients with typical imaging findings of meningioma. (3)

MR spectroscopy may provide additional information in differential diagnosis. Cho reflects membrane turnover, correlates with malignancy in astrocytic tumors, and forms high peaks in meningioma. The most common proton spectrum found in meningiomas is a high Cho peak with low or absent NAA and Cr and variable amounts of lactate. Most importantly, an unusually high ratio of Ala to Cr has been found in meningiomas because of the high Ala and low Cr content, and this is a relatively specific finding for meningioma. Alanine is seen as doublet centered at 1.47 ppm and inverts on the long-TE sequence. MR spectroscopy has

been shown to have some ability to differentiate histologically atypical meningiomas on the basis of lactate peak at 1.3 ppm. (3)

In our study we studied 2 cases of meningioma one of them was typical and one of them was atypical and both showed findings matching the fractionated findings in the previous paragraph, however limited number of cases limits our ability statistically accuracy to predict value of the examined tool.

Some similar studies

(Juan A et al., 2014) (13) Studied the added value of advanced over conventional magnetic resonance imaging in grading gliomas and other primary brain tumors

They analyzed 129 patients diagnosed with primary brain tumors (118 gliomas) classified as low-grade in 30 cases and high-grade in 99 cases.

And they found that Significant differences were obtained in high-grade tumors for conventional MRI variables (necrosis, enhancement, edema, hemorrhage, and neovascularization); high relative cerebral blood volume values (rCBV), low relative apparent diffusion coefficients (rADC), high ratio of N-acetyl-aspartate/creatine at short echo time (TE) and high choline/creatine at long TE. Among conventional MRI variables, the presence of enhancement and necrosis were demonstrated to be the best predictors of high grade in primary brain tumors (sensitivity 95.9%; specificity 70%). The best results in primary brain tumors were obtained for enhancement, necrosis, and rADC (sensitivity 98.9%; specificity 75.9%). Necrosis and enhancement were the only predictors of high grade in gliomas (sensitivity 97.6%; specificity 76%) when all the magnetic resonance variables were combined.

In our study we used only spectroscopy measurements in addition to conventional MRI findings and we used combined single and multivoxel spectroscopy in diagnosis.

(Aprile, et al, 2012) (14) performed a retrospective study on 65 patients with past clinical records of cerebral gliomas. They had all undergone a biopsy or a resection operation and they found that sensitivity was significantly highest evaluating both spectroscopic and perfusional data together (89.7%) in comparison with spectroscopy (74.4%) or perfusion (79.4%) alone. Instead specificity was slightly lower with all data (91.7%) in comparison with spectroscopy (95.8%) and perfusion (95.8%) alone. In conclusion, to characterize high grade gliomas it is more useful to evaluate spectroscopic and perfusional data together with respect only one of these techniques alone.

(Riyadh N. et al., 2006) (1) in a review of lectures stated that unfortunately, there are no unequivocal cutoff metabolite signal ratios that clearly distinguish neoplastic from non-neoplastic conditions. Published MR spectroscopic results showed a sensitivity of 79% and a specificity of 77% for a choline/NAA ratio of greater than 1 as an indicator of a neoplastic process.

A sensitivity of 87% and a specificity of 85% were achieved by using a logistical regression model with 10 input MR spectroscopic variables.

We were unable to find a reliable spectroscopic feature that distinguishes non-neoplastic from neoplastic conditions. However, we did find that a

choline/NAA cutoff ratio of 2.2 does reliably separate high-grade neoplasms from low grade neoplasms and non-neoplastic conditions.

Analysis of other metabolite peaks can also aid in grading primary neoplasms. High-grade neoplasms tend to have elevated lipid signal, which is often absent in low-grade neoplasms.

On the other hand, a high myo-inositol peak is more characteristic of lower grade neoplasms and gliomatosis cerebri (the latter are WHO grade III tumors but have advanced MR imaging features that are more in line with those of low-grade neoplasms).

(Andreas Bitsch, et al., 1999) (15) studied four and seven stereotactic needle brain biopsies were performed in three young adults with diagnostically equivocal findings for MS. Axonal density, gliosis, blood brain-barrier breakdown, and demyelinating activity of lesions were determined. Combined MR/MRS studies were performed (T1-weighted fast low-angle shot and single-voxel stimulated echo acquisition mode), and absolute metabolite levels were obtained with a user-independent fitting routine. Metabolite control values were obtained from a group of age-matched healthy volunteers (n540, age range, 20–25 years old). Alterations of metabolite levels of control subjects were considered significant when exceeding two standard deviations.

There were parallel decreases of N-acetylaspartate (21%–82%) and reductions of axonal density (44%–74%) in demyelinating plaques. Concomitant increases of choline (75%–152%) and myo-inositol (84%–160%) corresponded to glial proliferation elevated lactate was associated with inflammation.

The present data suggest that in vivo MRS indicates key pathologic features of demyelinating lesions. Multiple sclerosis (MS) is a chronic inflammatory

NB: -we mentioned this study in discussion as this is a rare pathologically proven entity, extremely rare to do stereotactic biopsy in MS nowadays.

(Abdel-Monem et al., 2014) (16) studied 36 patients with pathologically proven brain tumor and cMRI, MRS and diffusion weighted images before surgery.

This study stated that MR spectroscopy could differentiate benign from malignant tumors but was not useful in tumor grading. In the differentiation of malignant from benign tumors, N-acetylaspartate (NAA), Choline (Cho), Creatine, lactate/lipid, and alanin ratios were significant. Increase in lipid and alanin could distinguish metastases and meningiomas from other tumors. Increase in the lactate level correlated with the degree of malignancy. ADCs were effective for grading malignant tumors but not for distinguishing tumor types with the same grade. High grade malignant tumors had lower ADC values ($0.428 \pm 0.006 \cdot 10^{-3} \text{ mm}^2/\text{s}$) than did low grade malignant ($1.6 \pm 0.325 \cdot 10^{-3} \text{ mm}^2/\text{s}$), and benign ($1.200 \pm 0.707 \cdot 10^{-3} \text{ mm}^2/\text{s}$) tumors.

In our study we agree with the 1st component and disagree with the 2nd part which, as our study and may of the published studies status that MRS is aids not only differentiating malignant form non-malignant lesions and also for tumor grading.

(Rasha Elshafey et al., 2014) (17) Studied 45 patients (necrotic or cystic tumor (30 cases); brain abscess (15 cases) showing ring-shaped contrast enhancement on conventional MRI. 1.5-T 1HMR.

Spectroscopy and diffusion WI were performed and the results were ensured by stereotactic biopsy or aspiration procedures in surgically indicated cases and/or follow up.

This study showed that combined diffusion and spectroscopy has Sensitivity 88 (%) Specificity 100(%) PPV 100 (%) NPV 93 (%) Accuracy 95.5 (%).

This study showed similar results but focused on differentiation of pyogenic form neoplastic ring enhancing lesions.

The study concluded that combination of MRS with cMRI and calculated ADC values added more and more information to MR imaging in the differentiation and grading of brain tumors and were more useful when done together than each alone.

Limitations

During our stud the examination time is always a limiting factor and the need is very much to invent fast imaging sequences.

During all our study spectroscopy imaging located a mid-way between and subjective and objective methods of imaging and the examination accuracy is affected significantly by both technique and experience of the radiologist.

The technique is marked affected by lack of adequate shimming and in presence of magnetic field inhomogeneity.

The examination quality could be degraded in presence of metabolic foreign bodies (as sutures) or in presence of hemorrhage especially in single voxel spectroscopy than in multivoxel spectroscopy.

Recommendations for further studies

During our study we found almost no difficulty in diagnosis of high grade neoplasms and differentiating it from abscesses, yet the diagnosis of low grade neoplasm and differentiating it from non neoplastic lesions and well as from intermediate grade tumors is difficult, warranting further dedicated histopathological confirmed studies of low grade neoplasms on sufficient number of cases.

Most of our cases of abscesses were examined in stage of early and late capsule formation and its recommended to for further studies to assess cases in stage if early and late cerebritis and follow up spectroscopy to assess metabolic pattern of abscess evolution and if it helps to predict typed of organisms bases on metabolic pattern.

Serial MRS study in variable stages of demyelinating lesions and prediction of activity.

Restudying the sensitive and accuracy, positive predictive value and negative predictive value and the evolving high magnetic field power 3Tesla and 7 Tesla.

CONFLICT OF INTEREST STATEMENT

None to declare.

REFERENCES

- 1) Riyadh N. Al-Okaili, Jaroslaw Krejza et al., *RadioGraphics* 2006; 26:S173–S189.
- 2) Brant, William E and Clyde Helms, *Fundamentals of Diagnostic Radiology*, 3rd Edition Lippincott Williams & Wilkins 2007.
- 3) Antonios Drevelegas. *Imaging of Brain Tumors with Histological Correlations* Springer-Verlag Berlin Heidelberg 2011 second edition
- 4) Ping-Hong Lai^{1,4}, Shu-Shong Hsu^{2,4}, Yuk-Keung Lo^{3,4}, and Shang-Wu Ding *Acta Neurol Taiwan* 2004;13:107-113.
- 5) Pomper MG, Port JD New techniques in MR imaging of brain tumors. *Magn Reson Imaging Clin N Am* (2000) 8:691–713.
- 6) De Stefano N, Caramanos Z, Preul MC, Francis G, Antel JP, Arnold DL. In vivo differentiation of astrocytic brain tumors and isolated demyelinating lesions of the type seen in multiple sclerosis using ¹Hmagnetic resonance spectroscopic imaging. *AnnNeurol* 1998; 44: 273–8.
- 7) Law M, Cha S, Knopp EA, Johnson G, Arnett J, LittAW. High-grade gliomas and solitary metastases: differentiation by using perfusion and proton spectroscopicMR imaging. *Radiology* 2002; 222: 715–21.
- 8) Kapsalaki EZ, Gotsis ED, Fountas KN. The role of proton magnetic resonance spectroscopy in the diagnosis and categorization of cerebral abscesses. *Neurosurg Focus* 2008; 24: E7.
- 9) Li X, Lu Y, Pirzkall A, Mcknight T, Nelson SJ. Analysis of the spatial characteristics of metabolic abnormalities in newly diagnosed glioma patients. *J Magn Reson Imaging* 2002; 16: 229–37. Chapter 5: MRS in brain tumors.
- 10) Astrakas LG, Zurakowski D, Tzika AA et al., Noninvasive magnetic resonance spectroscopic imaging biomarkersto predict the clinical grade of pediatric brain tumors, *Clin Cancer Res* 2004; 10: 8220–8.
- 11) Lukas L, Devos A, Suykens JA, Vanhamme L, Howe FA, Majós C, et al. Brain tumor classification based on long echo proton MRS signals. *Artif Intell Med* 2004; 31: 73–89.
- 12) Peter B. Barker Alberto Bizzi Nicola De Stefano Rao P. Gullapalli Doris D. M. *LinClinical MR Spectroscopy Techniques and Applications* Cambridge University Press 2009.
- 13) Juan A Guzmán-De-Villoria^{1,2*}, José M Mateos-Pérez^{2,3}, Pilar Fernández-García¹, Enrique Castro¹ and Manuel Desco *Cancer Imaging* (2014) 14:35.
- 14) Aprile, C. Torni¹, P. Fiaschini¹, M. Muti, High-Grade Cerebral Glioma Characterization: Usefulness of MR Spectroscopy and Perfusion Imaging Associated Evaluation, the *Neuroradiology Journal* 25: 57-66, 2012.
- 15) Andreas Bitsch, Harald Bruhn, Vassilios Vougioukas, et al., Inflammatory CNS Demyelination: Histopathologic Correlation with in

Vivo Quantitative Proton MR Spectroscopy AJNR Am J Neuroradiol
October 1999.20:1619–1627.

- 16) Abdel-Monem N. Darweesh, Manal E. Badawy, Manal Hamesa, et al.,
Magnetic resonance spectroscopy and diffusion imaging in the
evaluation of neoplastic brain lesions, *The Egyptian Journal of
Radiology and Nuclear Medicine* (2014) 45, 485–493.
- 17) Rasha Elshafey, Omar Hassanein, Ahmed Shakal, Essam Mokbel H
proton MR spectroscopy and diffusion-weighted imaging in
discrimination between pyogenic brain abscesses and necrotic brain
tumors *The Egyptian Journal of Radiology and Nuclear Medicine*
(2014) 45, 889–896.