

## THE POSSIBLE PROTECTIVE EFFECTS OF OXYTOCIN ON CISPLATIN-INDUCED TOXICITY IN FEMALE RATS

Zeinab A. Rahman<sup>1\*</sup>, Wedad A. Hassan<sup>2</sup>, Amany El Garhy<sup>3</sup>

<sup>1</sup>Assistant professor in pharmacology department of national organization of drug control and research, **EGYPT**

<sup>2,3</sup>Lecturer in pharmacology department of national organization of drug control and research, **EGYPT**

\*Corresponding author: cat3pink@yahoo.com

### ABSTRACT

*The present study aimed to assess the protective effect of oxytocin against cisplatin-induced liver, renal spleen and ovarian toxicities in female Sprague Dawley rats. Cisplatin (7.5 mg/kg, i.p. single dose) caused significant increase in blood urea, serum creatinine, liver enzymes: AST, ALT and alkaline phosphatase. Cisplatin caused decrease in catalase and reduced glutathione meanwhile it caused increase in the malondialdehyde content of kidney, liver and spleen homogenates. On the other hand, administration of oxytocin (800 µg/kg i.p) for six days with injection of a single dose of cisplatin onset of the day 3, ameliorated the cisplatin-induced nephrotoxicity and hepatotoxicity as indicated by the restoration of kidney, liver functions and oxidative stress biomarkers. Furthermore, oxytocin reduced the histopathological changes induced by cisplatin and caused decreased expression of caspase-3 in immunohistochemical studies of liver, kidney, spleen and ovarian tissues. In conclusion, oxytocin showed protective effects against cisplatin-induced toxicity in female rats due to its antioxidant and immunomodulatory functions.*

**Keywords:** cisplatin, oxytocin, nephrotoxicity, liver enzymes, immunomodulation

### INTRODUCTION

Cisplatin (cis-diamminedichloroplatinum (CDDP)) is one of the most effective chemotherapeutic agent widely used in the treatment of a variety of malignancies including head, neck, ovarian, and testicular cancers (Badary et al. 2005). However, the full clinical utility of cisplatin is limited by its nephrotoxicity (Schrier 2002). Tubular toxicity in the form of apoptosis and necrosis (Chirino and Pedraza-Chaverri 2009), vascular factors and inflammation have been implicated in the pathogenesis of cisplatin-mediated nephrotoxicity (Pabla and Dong 2008). Cisplatin can induce hepatotoxicity after having administered at high doses. Oxidative stress appears to play an important role in cisplatin induced hepatotoxicity (Cersosimo 1993). In both animal and human studies, Cisplatin has been shown to cause ovarian injury, leading to ovarian dysfunction, changes in the estrous cycle, increased follicular apoptosis, and a reduction in the number of anti-Mullerian

hormone secreting follicles (Yucebilgin et al 2004). The overproduction of reactive oxygen species (ROS) has been implicated in the pathophysiology of cisplatin - induced cytotoxicity by increasing lipid peroxidation, mitochondrial damage and DNA injury (Deavall et al 2012). Oxytocin (OT) is a peptide hormone exerting its physiological and biological actions via its G-protein coupled receptor. OT receptors are widespread in the nervous system, vascular smooth muscle, myocardium, thymus, pancreas and adipocytes (Gutkowska and Jankowski 2009). Oxytocin may have beneficial effects against cisplatin-induced neurotoxicity (Akman et al. 2015). Oxytocin has a protective role in hepatic ischemia-reperfusion injury and its protective effect in the liver appears to be dependent on its inhibitory effect on neutrophil infiltration (Düşünceli et al. 2008). Oxytocin has a powerful antioxidant effect that can alleviate the cisplatin-induced nephrotoxicity through inhibition of NADPH oxidase and P38 MAPK and prevents apoptosis and inflammation resulting in improvement of kidney functions (Rashed et al. 2011). The ameliorative effects of oxytocin against cisplatin renal toxicity was studied also by (Elberry et al. 2013).

## MATERIALS AND METHODS

### Chemicals:

-Cisplatin (CIS) was obtained from EIMC United Pharmaceuticals, Egypt and was given i.p. in a single dose of (7.5 mg/kg).

-Oxytocin (ampoule 1ml contain 5 I.U.) from MINAPHARM Pharmaceuticals and was given (800 µg/kg i.p. for six days).

### Animals:

Female adult Sprague-Dawley rats weighing 230-260g were obtained from the breeding colony maintained at the animal house of the National Organization for Drug Control and Research, NODCAR, Egypt. Animals were caged in four groups, given food and water *ad libitum* and maintained at 21–24°C and 40–60% relative humidity with 12-h light–dark cycles. Animals were subjected to an adaptation period of two weeks in the animal house before experiments.

### Experimental design:

Forty female adult Sprague-Dawley rats were allocated into four groups (10 rats / each) as follows:

**Group 1:** Received saline and served as control.

**Group 2:** Received single dose of cisplatin (7.5mg/kg; i.p)

**Group 3:** Received oxytocin in a dose of (800 µg/kg i.p.) for six days

**Group 4:** Received oxytocin in a dose of 800 µg/kg i.p for three days then single dose of cisplatin (7.5 mg/kg) and continued with oxytocin in a dose of 800 µg/kg i.p for three days.

### Serum and Tissue Preparation:

On the sixth day after cisplatin injection, blood samples were taken under light ether anesthesia in non-heparinized tubes. Serum was separated by centrifugation for 20 min at 4000 g and stored at – 20°C. Blood urea nitrogen and creatinine were measured using Biodiagnostic reagent kit according to the methods described by (Fawcett and Soctt 1960) and (Schirmeister, 1964)

respectively. Liver function parameters as total protein, albumin, alkaline phosphatase (ALP), Glutamic-Pyruvic Transaminase (GPT), and Glutamic-Oxalo acetic Transaminase (GOT) were estimated using a Biodiagnostic reagent kit according to the methods described by (Gornal et al 1949),( Doumas et al 1971), (Belfield and Goldberg 1971)and (Reitman and Frankel 1957) respectively. The kidneys, liver, spleen and ovaries were rapidly isolated and washed with ice-cold isotonic saline (0.9%) then stored at -80°C till they were homogenized in 50 mM phosphate buffer (pH 7.4) using electronic homogenizer (Ezister Daihan Scientific Co., Ltd., Korea) to prepare 10 % w/v homogenate. The homogenate was then made into aliquots and was used for the determination of organs contents of MDA according to the method of (Satoh,1978). GSH was measured according to the method described by (Beutler et al. 1963), and enzymatic activity of CAT was measured according to the method described by (Aebi, 1984).

#### **Histopathological Examination of the Kidney, Liver, Spleen and Ovaries**

Autopsy samples were taken from the organs of rats in different groups and fixed in 10% neutral buffered formalin for 24 hours and decalcification was done on formic acid. Then washing in tap water, and serial dilutions of alcohol (methyl, ethyl and absolute) were used for dehydration. Specimens were cleared in xylene and embedded in paraffin at 56°C in hot air oven for 24 hours. Paraffin bees wax tissue blocks were prepared for sectioning at 4 microns thickness by sledge microtome. The obtained tissue sections were collected on glass slides, de-paraffinized, stained by hematoxylin & eosin stain and then examined by the light electric microscope (Bancroft, 1996).

#### **CASP-3 Immunohistochemical Examination**

Prior to immune-histochemical staining, paraffin sections were mounted onto slides of 5mm micron thickness, and then de-paraffinized and rehydrated through xylene and alcohol. Antigen retrieval was performed by placing the sections for 20 min. in citrate buffer (Thermo Fisher Scientific, Fremont, USA; pH 6.0) at the boiling point then cooled. Active caspase-3 was detected when sections were incubated with the rabbit polyclonal anti-Casp-3 (CPP32) primary antibody (1:200; Thermo Fisher Scientific) overnight at 4°C. After washing with phosphate buffered saline (PBS), they were incubated with the biotinylated secondary antibody at 37°C for 30 min then incubated with the Vector Elite ABC kit (Vector Laboratories, Burlingame, CA, USA) at 37°C for 30 min. After another wash with PBS, the antibody-biotin-avidin-peroxidase complex was developed using diaminobenzidine tetra hydrochloride (DAB Substrate Kit, Vector Laboratories Inc.). Sections were counterstained with hematoxylin, dehydrated and, cleared in xylene, and cover slipped. The reaction appeared as a brown cytoplasmic reaction.

#### **STATISTICAL ANALYSIS**

Statistical significance of differences between means of groups was performed using the SPSS version 16 (Chicago, IL, USA), while the graphs were drawn using a prism computer program (Graph Pad software Inc. V5, San Diego, CA, USA). One-way analysis of variance (ANOVA) was employed to calculate the

statistical significance followed by Tukey-Kramer Multiple Comparison Test. A value of  $P < 0.05$  was considered significant.

## RESULTS

**Table 1.** Effects of administration of cisplatin and oxytocin on liver and kidney functions in female rats

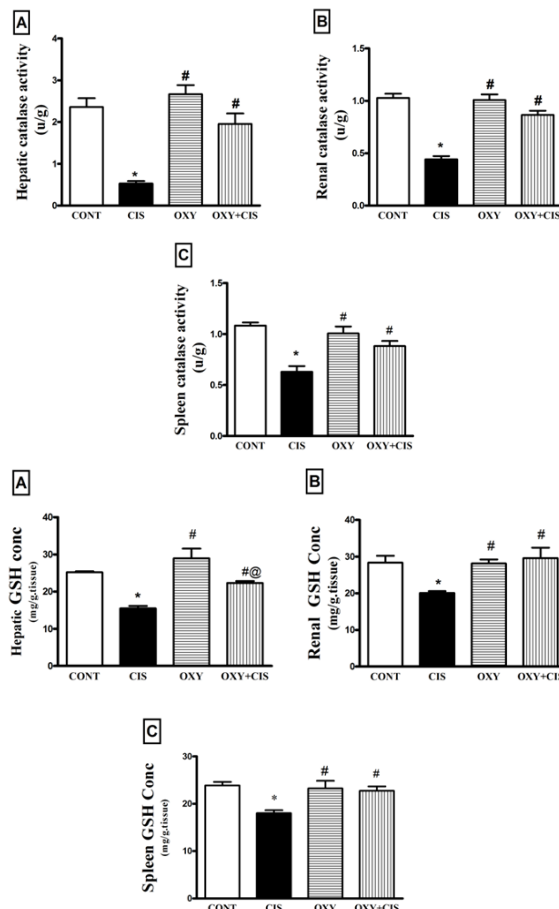
Groups	CREATININE (mg/dl)	UREA (mg/dl)	ALT (U/L)	AST (U/L)	ALK (mg/dl)	Albumin (g/dl)	Total Protein (g/dl)
Control	0.5767±0.014	24.83±1.641	43.17±1.662	45.48±0.4615	40.33±1.116	3.233±0.042	8.583±0.2386
Cisplatin 7.5mg/kg	2.298±0.3139*	129.8±9.931*	121.7±12.9*	193.2±15.54*	250.7±28.06*	3.700±0.35	8.833±0.1382
Oxytocin 800 µg/kg	0.5550±0.032#	19.83±1.537#	30.67±1.96 #	139.0±16.7*#	165.5±23.47*#	3.750±0.33	8.767±0.5129
Cisplatin(7.5mg/kg)+ Oxytocin(800 µg/kg)	1.230±0.03*#@	97.0±10.4*#@	39.50±4.56 #	111.5±2.14*#	62.83±9.25#@	3.483±0.060	8.500±0.1862

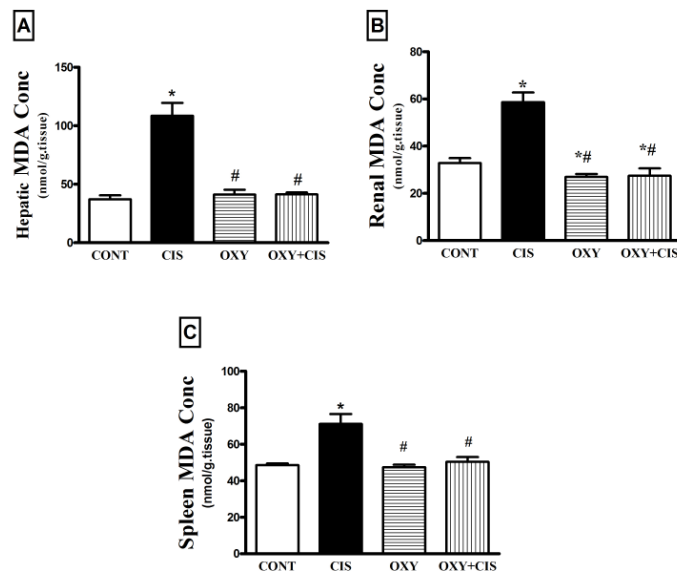
Data are expressed as means ± SEM. using one-way ANOVA followed by the Tukey-Kramer test for multiple comparisons test. Significance occurred at  $P < 0.05$ .

\*Significantly different from the normal control group.

#Significantly different from the cisplatin group

@ Significantly different from oxytocin group





**Figures A, B & C.** Effects of administration of cisplatin and oxytocin on liver, kidney and spleen catalase, GSH and MDA in female rats

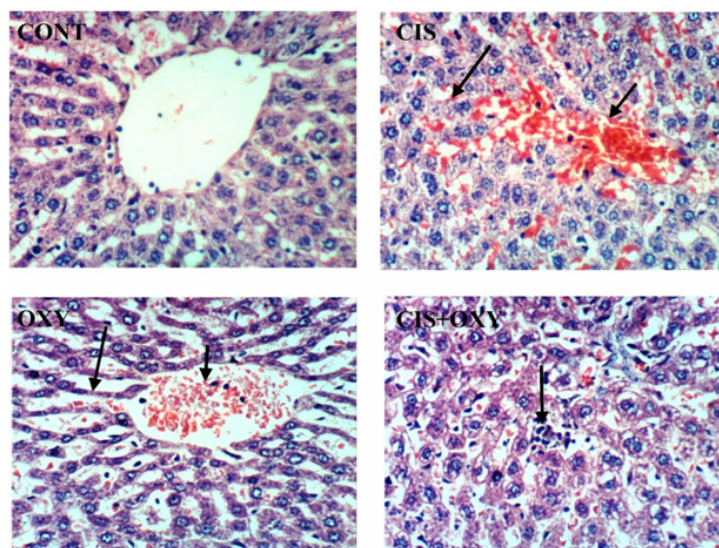
Data are expressed as means  $\pm$  SEM using one-way ANOVA followed by the Tukey–Kramer test for multiple comparisons test. Significance occurred at  $P < 0.05$ .

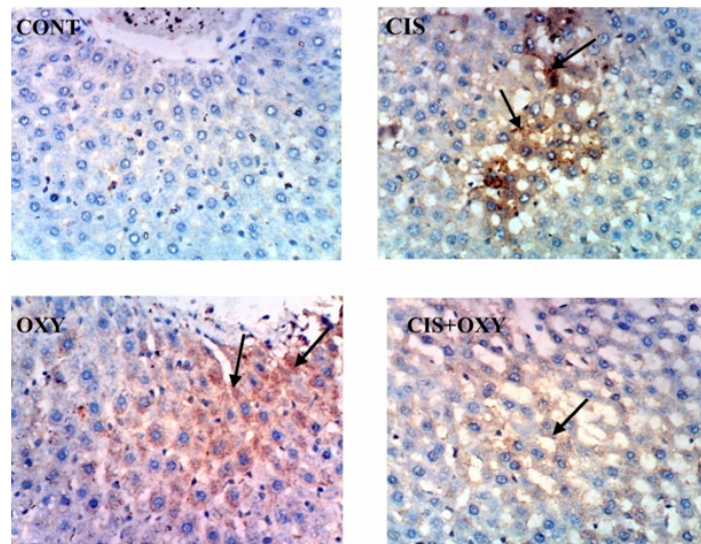
\*Significantly different from the normal control group.

#Significantly different from the cisplatin group

@ Significantly different from oxytocin group

## RESULTS OF HISTOPATHOLOGICAL AND IMMUNOHISTOCHEMICAL STUDIES OF LIVER OF FEMALE RATS

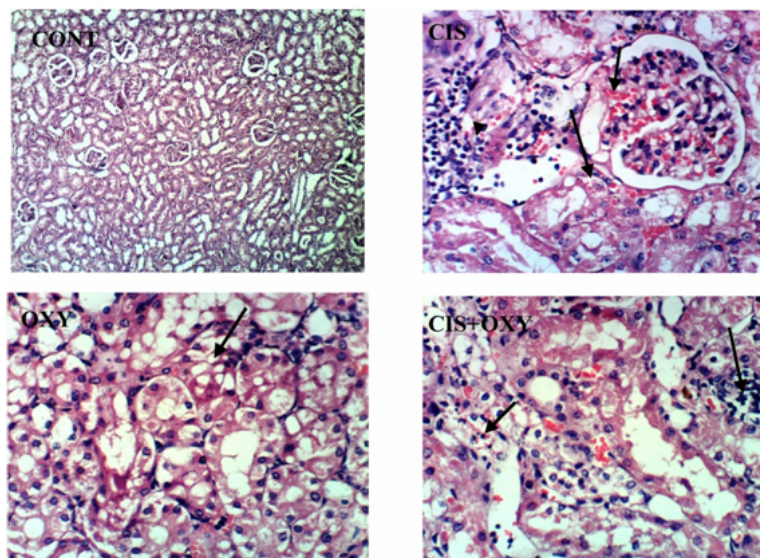


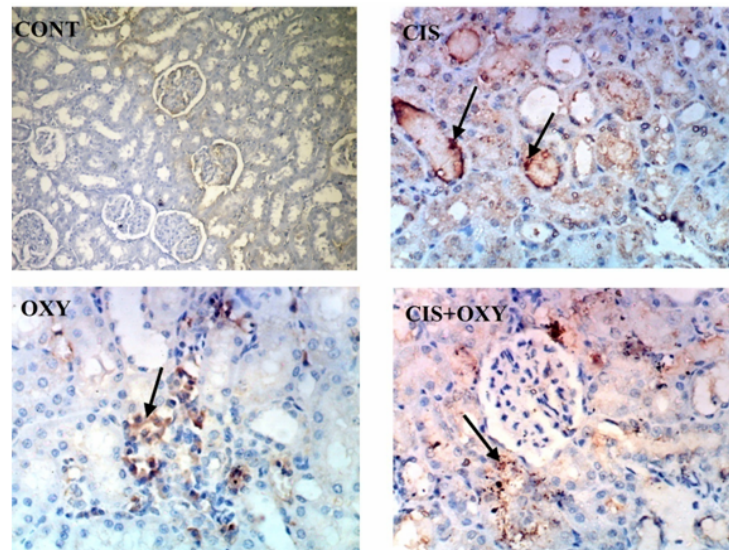


Liver of rat treated with cisplatin (CIS) showing congestion of central vein and hepatic sinusoids. Liver of rat treated with oxytocin (OXY) showing congestion of central vein and atrophy of hepatic cords with dilatation of hepatic sinusoids. Liver of rat treated with cisplatin+oxytocin (CIS+OXY) showing focal hepatic necrosis associated with inflammatory cells infiltration.

*Liver of rat treated with cisplatin (CIS) showing strong positive expression of caspase (strong immunopositivity for caspase) (brown colour). Rat treated with oxytocin (OXY) showing moderate positive expression of caspase. Liver of rat treated with cisplatin +oxytocin (CIS+OXY) showing weak positive expression of caspase*

#### RESULTS OF HISTOPATHOLOGICAL AND IMMUNOHISTOCHEMICAL STUDIES OF KIDNEY OF FEMALE RATS

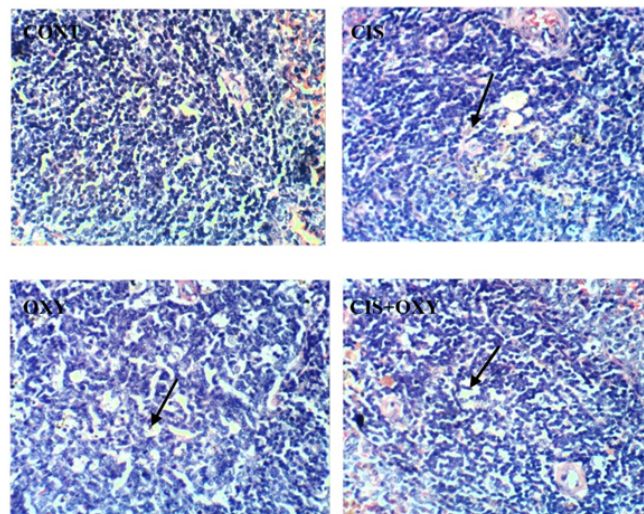


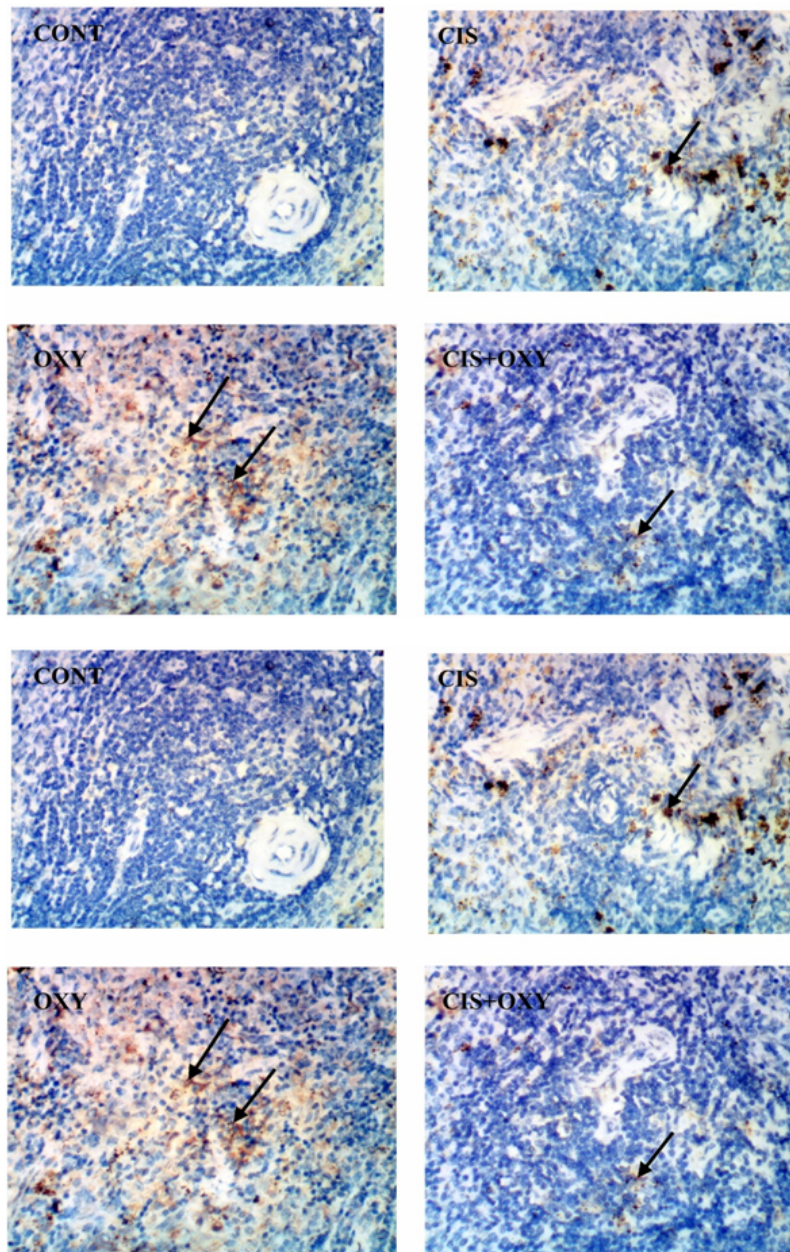


Kidney of rat treated with cisplatin (CIS) showing congestion of glomerular tuft, vacuolation of renal tubular epithelium and focal necrosis of renal tubules associated with inflammatory cells infiltration. Kidney of rat treated with oxytocin (OXY) showing vacuolation of renal tubular epithelium. Kidney of rat treated with cisplatin + oxytocin (CIS+OXY) showing vacuolation and necrosis of renal tubules associated with inflammatory cells infiltration.

*Kidney of rat treated with cisplatin (CIS) showing strong positive expression of caspase (strong immunopositivity for caspase) (brown colour). kidney of rat treated with oxytocin (OXY) showing moderate positive expression of caspase. kidney of rat treated with cisplatin + oxytocin (CIS+OXY) showing moderate positive expression of caspase (X 400)*

#### RESULTS OF HISTOPATHOLOGICAL AND IMMUNOHISTOCHEMICAL STUDIES OF SPLEEN OF FEMALE RATS



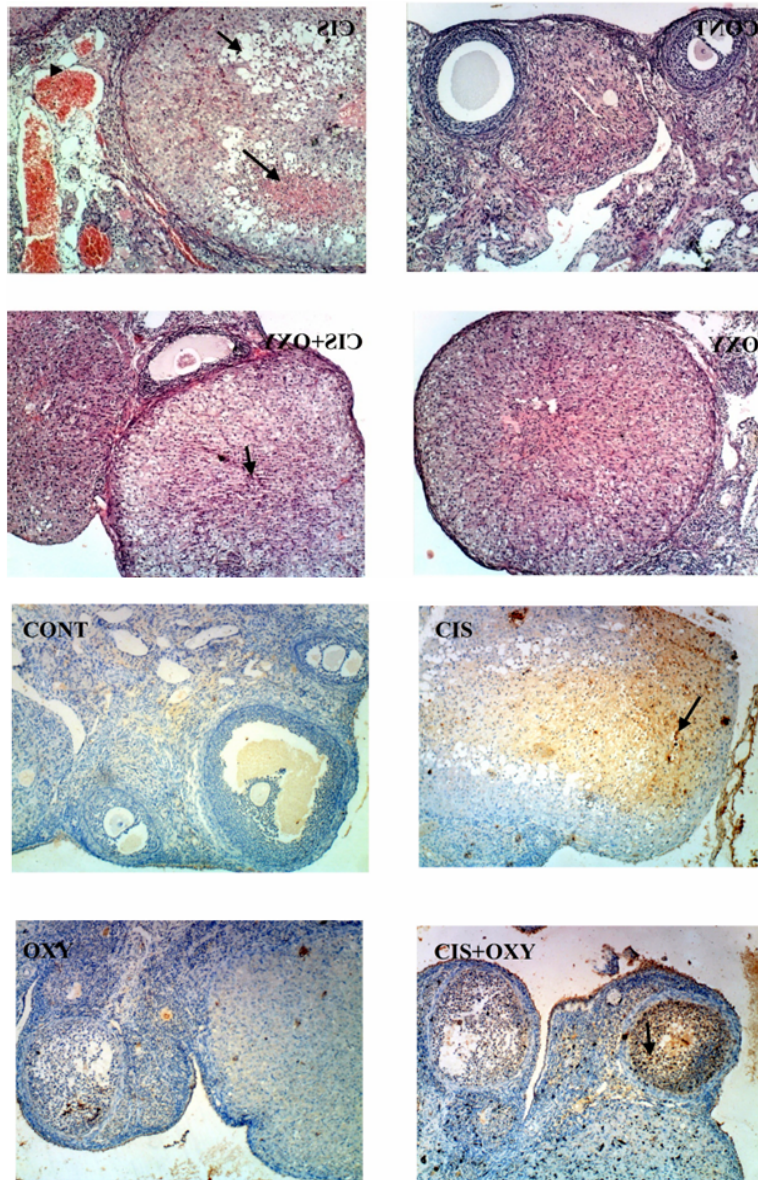


Spleen of rat treated with cisplatin (CIS) showing slight lymphocytic necrosis and depletion. Spleen of rat treated with oxytocin (OXY) showing lymphocytic necrosis and depletion. Spleen of rat treated with cisplatin + oxytocin (CIS+OXY) showing slight lymphocytic necrosis and depletion

*Spleen of rat treated with cisplatin (CIS) showing moderate positive expression of caspase (immunopositivity for caspase) (brown colour). Spleen of rat treated with oxytocin (OXY) showing strong positive expression of caspase. Spleen of rat treated with cisplatin + oxytocin (CIS+OXY) showing weak positive expression of caspase*



### RESULTS OF HISTOPATHOLOGICAL AND IMMUNOHISTOCHEMICAL STUDIES OF OVARIES OF FEMALE RATS



Ovary of rat treated with cisplatin (CIS) showing vacuolation and necrosis of lutein cells and congestion of interstitial blood vessels. Ovary of rat treated with oxytocin (OXY) showing no histopathological changes. Ovary of rat treated with cisplatin + oxytocin (CIS+OXY) showing necrosis of some lutein cells.

*Ovary of rat treated with cisplatin (CIS) showing strong positive expression of caspase (strong immunopositivity for caspase) (brown colour). Ovary of rat treated with oxytocin (OXY) showing no expression of caspase. Ovary of rat treated with cisplatin + oxytocin (CIS+OXY) showing weak positive expression of caspase*

## DISCUSSION

In this study, hepatotoxicity, nephrotoxicity, spleen and ovarian toxicities induced by cisplatin was diagnosed by the alterations of the biochemical, histological and immunohistochemical parameters. Oxidative stress was detected with cisplatin administration in the form of increased hepatic, renal and spleen malondialdehyde (MDA) levels and reduced glutathione (GSH) and catalase activities compared to the control group. Palipoch and Punsawad (2013) investigated the involvement of oxidative stress in the pathogenesis of cisplatin-induced liver and kidney injury and found that oxidative stress was implicated in the pathogenesis of liver and kidney injury causing biochemical and histological alterations

In this study, Oxytocin co- administration reduced oxidative stress induced by cisplatin. Hassan et al. (2010) studied cisplatin-induced hepatotoxicity and used protection by using natural products-derived antioxidants. Oxytocin reduces consumption of glutathione and superoxide dismutase, inhibits NADPH oxidase and myeloperoxidase, elevates nitric oxide levels and prevents apoptosis and inflammation. Oxytocin protected rats from cisplatin -induced nephrotoxicity. Such protection is attributed, at least in part, to its antioxidant activity and through anti-apoptotic mechanisms (Erbas et al. 2014)

In this study, histopathological examination of Ovaries of rats treated with cisplatin showing vacuolation and necrosis of lutein cells and congestion of interstitial blood vessels and by co-administration of oxytocin these changes are decreased. Oxytocin could lessen the cisplatin -induced ovarian damage and improve follicular reserve by preventing oxidative damage (Erbas et al. 2014).

In this study, Immunohistochemical results showed apoptosis and positive expression of caspase 3 with cisplatin administration in all organs and this immunological reaction was modulated by adding oxytocin. Ramesh and Reeves (2003) studied the tumor necrosis factor (TNF) R2-mediated apoptosis and necrosis in cisplatin-induced acute renal failure also, Padilla et al. (2003) found that Oxytocin treatment decreased cisplatin-induced over-expression of C-reactive protein expression which could activate autologous complement.

In rats, Oxytocin could exert antioxidant properties and modulate immune and anti-inflammatory responses in several inflammation and sepsis-induced animal models (Alizadeh et al 2012). Similarly in human, studies demonstrated that Oxytocin decreased the levels of pro-inflammatory mediators in lipopolysaccharide-induced inflammatory response and endotoxemia (Wang et al.2015)

## CONCLUSION

This study demonstrates that oxytocin has a protective role in cisplatin-induced toxicity in liver, kidney, spleen and ovaries in rats via its antioxidant and immuno-modulatory effects. Based on these findings, oxytocin may be considered as a potential agent that can be used for the prevention of cisplatin-induced toxicity.

## REFERENCES

- 1) Aebi, H. (1984): *Methods Enzymol.*; 105: 121-126.
- 2) Akman T, Akman L, Erbas O, Cosan M, Taskiran D and Ozsaran A (2015): The Preventive Effect of Oxytocin to Cisplatin-Induced Neurotoxicity: An Experimental Rat Model. *Bio Med Research International*. Research Article. ID 167235, 5 p.
- 3) Alizadeh AM, Faghihi M and Khori V (2012): Oxytocin protects cardiomyocytes from apoptosis induced by ischemia-reperfusion in rat heart: role of mitochondrial ATP-dependent potassium channel and permeability transition pore. *Peptides*; 36(1): 71-77.
- 4) Badary O, Abdel-Maksoud S, Ahmed W and Owieda G (2005): Naringenin attenuates cisplatin nephrotoxicity in rats. *Life Sci*; 76: 2125–2135.
- 5) Bancroft J.D, Stevens A and Turner DR (1996): *Theory and practice of Histological Techniques*. Fourth Ed. Churchill living stone, New York, London, San Francisco, Tokyo
- 6) Belfield A. and Goldberg D.M. (1971): Revised assay for serum phenyl phosphatase activity using 4-amino-antipyrine. *Enzyme J. Clin. Path.*; 12: 561- 573.
- 7) Beutler E, Duron O and Kelly MB (1963): *J.Lab. Clin. Med.*; 61:882.
- 8) Cersosimo, R.J (1993): Hepatotoxicity associated with cisplatin chemotherapy. *Annals of Pharmacotherapy* 27(4):438-41.
- 9) Chirino Y. and Pedraza-Chaverri J. (2009): Role of oxidative and nitrosative stress in cisplatin-induced nephrotoxicity. *Exp Toxicol Pathol*; 61:223
- 10) Deavall D.G, Martin E.A, Horner J.M. and Roberts R (2012): Drug-induced oxidative stress and toxicity. *Journal of Toxicology*; 13 pages. 645460
- 11) Dumas B.T, Watson W.A and Biggs H.G (1971): Albumin standards and the measurement of serum albumin with bromocresolgreen. *Clin. Chim. Acta*, 31(1):87-96.
- 12) Düşünceli F, Işeri SO, Ercan F, Gedik N, Yeğen C. and Yeğen B.C. (2008): Oxytocin alleviates hepatic ischemia-reperfusion injury in rats. *Peptides*; 29(7): 1216-22.
- 13) Elberry A.A, Refaie S.M, Kamel M, Ali T, Darwish H. and Ashourg O. (2013): Oxytocin ameliorates cisplatin-induced nephrotoxicity in Wistar rats. *Ann Saudi Med* 33:57-62.
- 14) Erbaş O, Akman L, Yavaşoğlu A, Cosan T.M, Akman T. and Taskiran D. (2014): Oxytocin Improves Follicular Reserve in a Cisplatin-Induced Gonadotoxicity Model in Rats. *Biomed Res Int.*; 703691
- 15) Erbas O, Korkmaz H.A, Oltulu F, Aktug H, Yavasoglu A, Akman L, Solmaz V. and Taskiran D. (2014): Oxytocin alleviates cisplatin-induced renal damage in rats Iran J Basic Med Sci. 17(10): 747–752.
- 16) Fawcett J.K and Soctt J.E. (1960): A rapid and precise method for the determination of urea. *J. Clin. Path.*; 13:156-159.

- 17) Gornal A.C, Bardawill C.J and David M.M (1949): J. Biol. Chem.; 177:751.
- 18) Gutkowska J. and Jankowski M. (2009): Oxytocin: Old Hormone, New Drug Review. *Pharmaceuticals*, 2(3), 168-183.
- 19) Hassan I, Chibber S and Naseem I (2010): Ameliorative effect of riboflavin on the cisplatin induced nephrotoxicity and hepatotoxicity under photoillumination. *Food Chem. Toxicol.*, 48 (8–9): 2052-2058.
- 20) Pabla N. and Dong Z. (2008): Cisplatin nephrotoxicity: mechanisms and renoprotective strategies. *Kidney Int*; 73:994-100.
- 21) Padilla ND, Bleeker WK, Lubbers Y, Rigter GM, Van Mierlo GJ and Daha MR (2003): Rat C-reactive protein activates the autologous complement system. *Immunology J*; 109:564-571.
- 22) Palipoch S. and Punsawad C (2013): Biochemical and Histological Study of Rat Liver and Kidney Injury Induced by Cisplatin. *J Toxicol. Pathol.* 26: 293–299 Original Article
- 23) Ramesh G. and Reeves WB. (2003): TNFR2-mediated apoptosis and necrosis in cisplatin-induced acute renal failure. *Am J. of Renal Physiol.*; 285:610–618.
- 24) Rashed A L, Hashemb M R and Solimane MH (2011) :Oxytocin inhibits NADPH oxidase and P38 MAPK in cisplatin-induced nephrotoxicity.*J. of Biomedicine& Pharmacotherapy*, V. 65, 7, 474-480.
- 25) Reitman S. and Frankel F.(1957): Colorimetric methods for determination of serum glutamic oxalo acetic and glutamic pyruvic transaminase activities. *Am. J. Clin. Path.*, 28: 26 -34.
- 26) Satoh, K. (1978): *Clinica Chimica Acta*, 90:37
- 27) Schirmeister, J. (1964): Determination of creatinine in serum. *Dtsch. med Wschr.*; 89:1940.
- 28) Schrier R.W. (2002): Cancer therapy and renal injury. *J Clin.Invest*; 100:743-745.
- 29) Wang P., Yang H., Tiana, S., Wang L., Wangc S., Zhanga F. and Wanga Y. (2015): Oxytocin-secreting system: A major part of the neuroendocrine center regulating immunologic activity *Journal of Neuroimmunology*, Vol. 289, P. 152-161.
- 30) Yucebilgin MS, Terek MC and Ozsaran A (2004): Effect of chemotherapy on primordial follicular reserve of rat: an animal model of premature ovarian failure and infertility. *Australian and New Zealand Journal of Obstetrics and Gynaecology*; 44(1):6-9.